

ΤΟΠΟΘΕΤΗΣΗ ΠΡΟΣΩΡΙΝΟΥ ΚΕΝΤΡΙΚΟΥ ΦΛΕΒΙΚΟΥ ΚΑΘΗΤΗΡΑ

ΠΑΝΑΓΑΚΟΥ ΣΤΕΛΛΑ

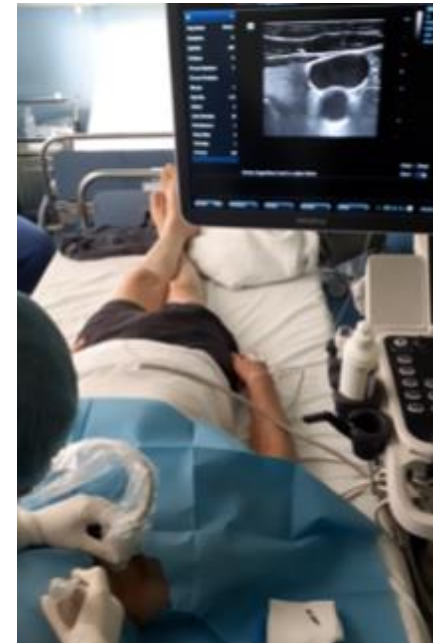ΕΙΔ/ΝΗ ΝΕΦΡΟΛΟΓΙΑΣ

ΓΝ ΠΑΠΑΓΕΩΡΓΙΟΥ

15

ΠΕΡΙΦΕΡΕΙΑΚΗ
ΔΙΗΜΕΡΙΔΑ

ΕΛΛΗΝΙΚΗΣ ΕΤΑΙΡΕΙΑΣ
ΑΙΜΑΦΑΙΡΕΣΗΣ



ΕΛΛΗΝΙΚΗ ΕΤΑΙΡΕΙΑ
ΑΙΜΑΦΑΙΡΕΣΗΣ

ΙΣΤΟΡΙΚΗ ΑΝΑΔΡΟΜΗ

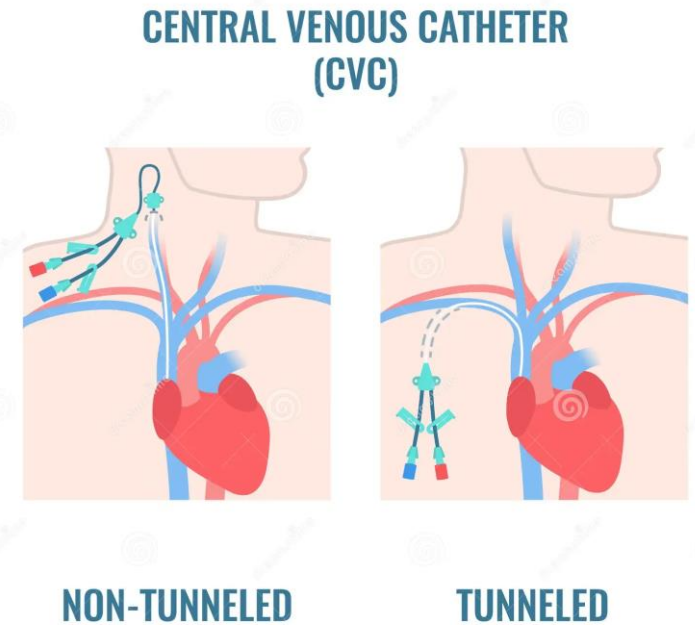
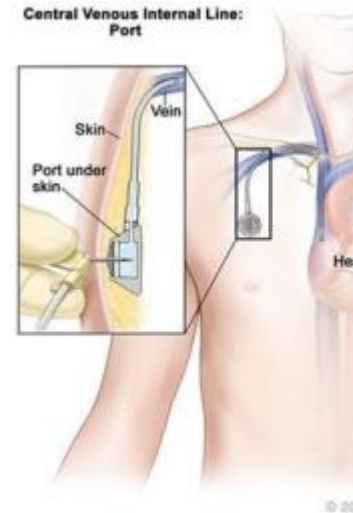
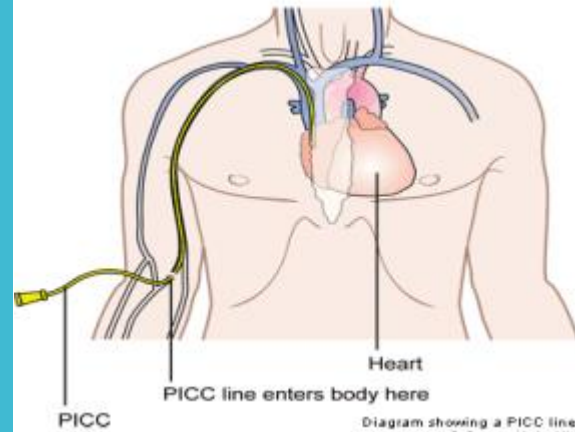
- **1929, Forssman W.**
- **1940, οι Andre Counard και Dickinson Richards**
- Το **1956**, οι **Forssmann, Counard και Richards** έλαβαν Νόμπελ Ιατρικής για τα επιτεύγματά τους στην κεντρική φλεβική πρόσβαση
- **1960**, τεχνική **Seldinger** (catheter over guide wire)
- **1970**, καθετήρας με υποδόριο τμήμα-σήραγγα (tunnel)
- Το **1982** έγινε η πρώτη αναφορά της χρήσης υπερήχων ως μέσο καθοδήγησης της τοποθέτησης της κεντρικής φλεβικής γραμμής, έγινε από τον **Peters**



Werner Forssmann

ΕΙΔΗ ΚΦΚ

- Περιφερικά εισαγόμενοι κεντρικοί φλεβικοί καθετήρες (PICC)
- Εμφυτεύσιμοι (ports ή port-a-cath)
- Με υποδόριο κανάλι (tunneled)
- Χωρίς υποδόριο κανάλι (non-tunneled)



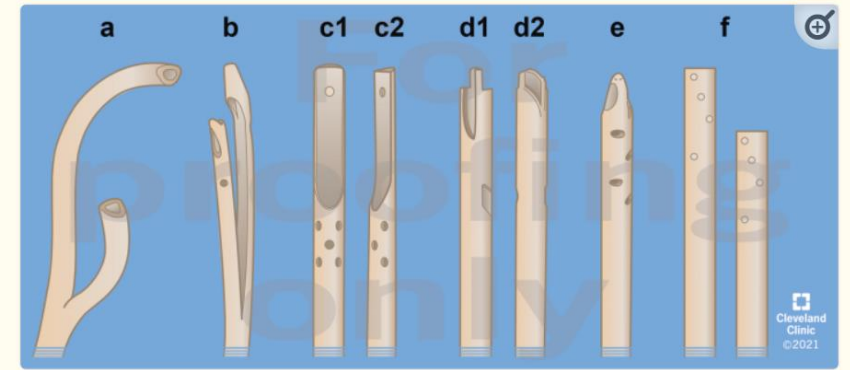
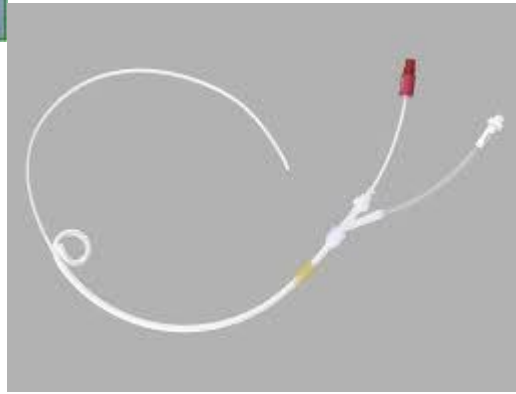
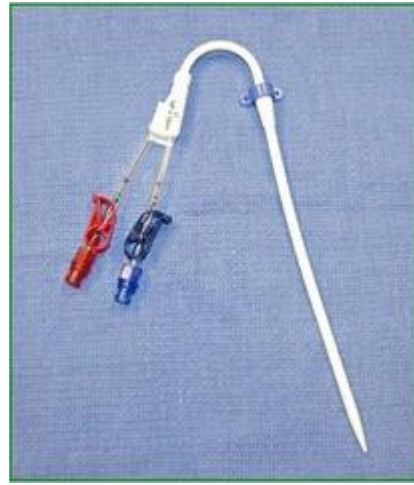
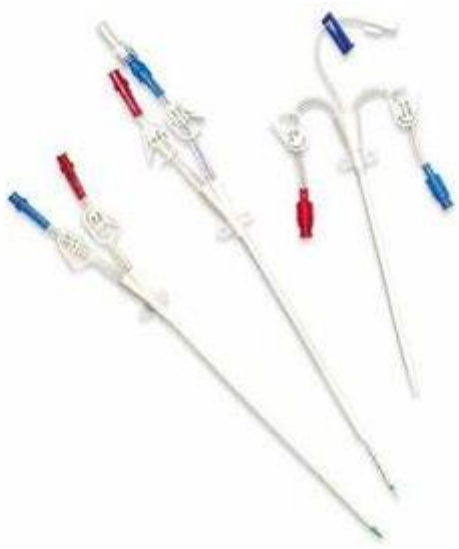
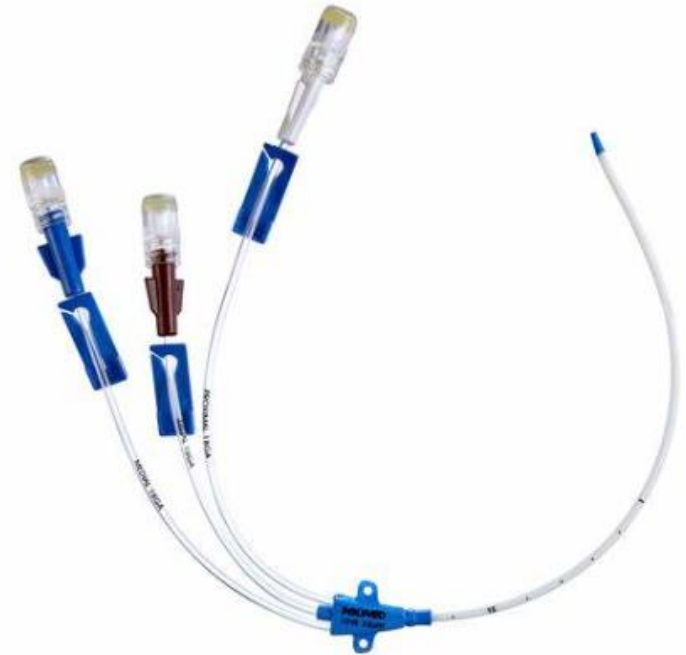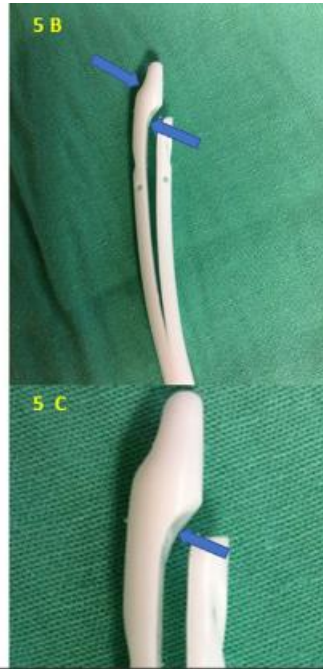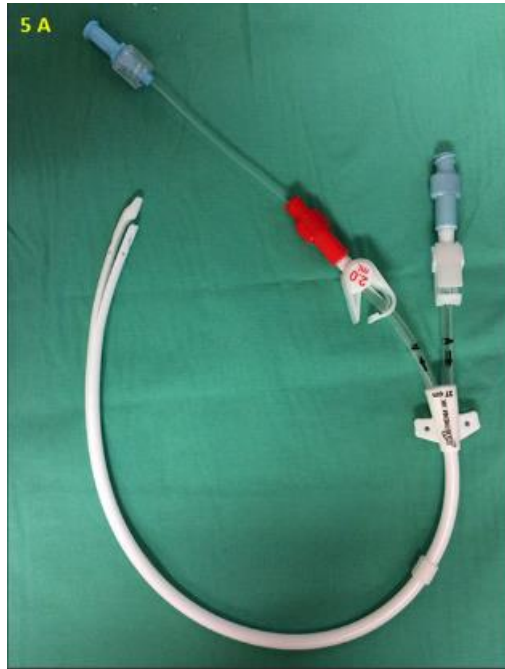Figure 1

Tunneled hemodialysis catheter tips. (a) Split tip with preformed curved tips. (b) Split tip standard. (c) c1/c2—step tip. (d) d1/d2—symmetric tip with side slots. (e) Symmetric tip with side holes. (f) Dual catheter (e.g., Tesio twin catheter).



ΘΕΣΕΙΣ ΤΟΠΟΘΕΤΗΣΗΣ

1 Έσω σφαγίτιδα φλέβα

2 Μηριαία φλέβα

3 Υποκλείδιος φλέβα

TABLE
7.1

Selected Factors Favoring Different Temporary (Nontunneled) Hemodialysis Catheter Insertion Sites

- 1. Right internal jugular**
 - Critically ill and bed-bound with body mass index >28
 - Postoperative aortic aneurysm repair
 - Ambulatory patient/mobility required for rehabilitation
- 2. Femoral**
 - Critically ill and bed-bound with body mass index <24
 - Tracheostomy present or planned in near-term
 - Need for long-term hemodialysis access present, highly likely or planned
 - Emergency dialysis required plus inexperienced operator and/or no access to ultrasound
- 3. Left internal jugular**
 - Contraindications to right internal jugular and femoral sites
- 4. Subclavian**
 - Contraindications to internal jugular
 - Right side to be used preferentially

Source: Reprinted by permission from Macmillan Publishers Ltd: Clark EG, Barsuk JH. Temporary hemodialysis catheters: recent advances. *Kidney Int.* 2014. doi:10.1038/ki.2014.162.

ANATOMIA

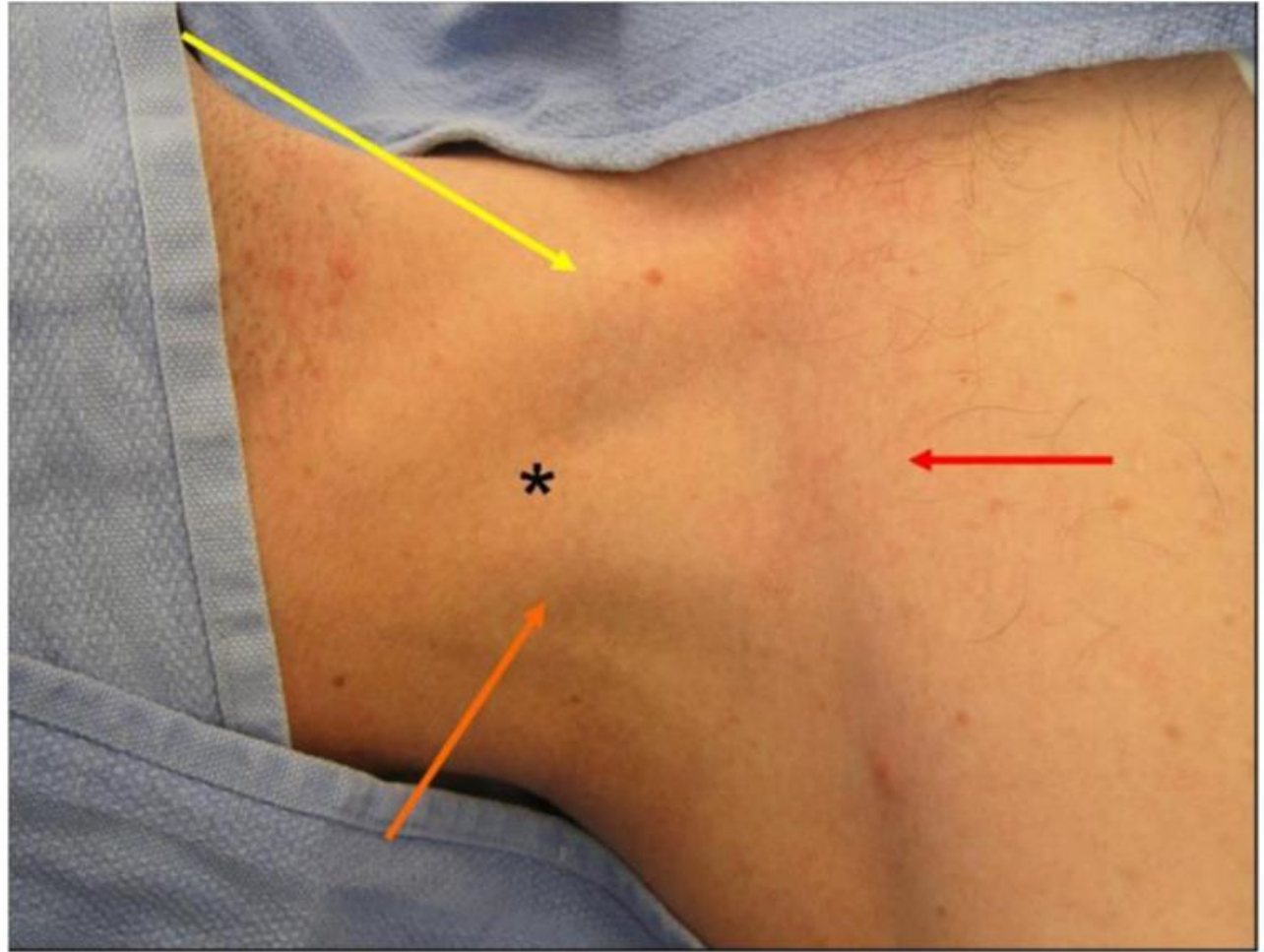
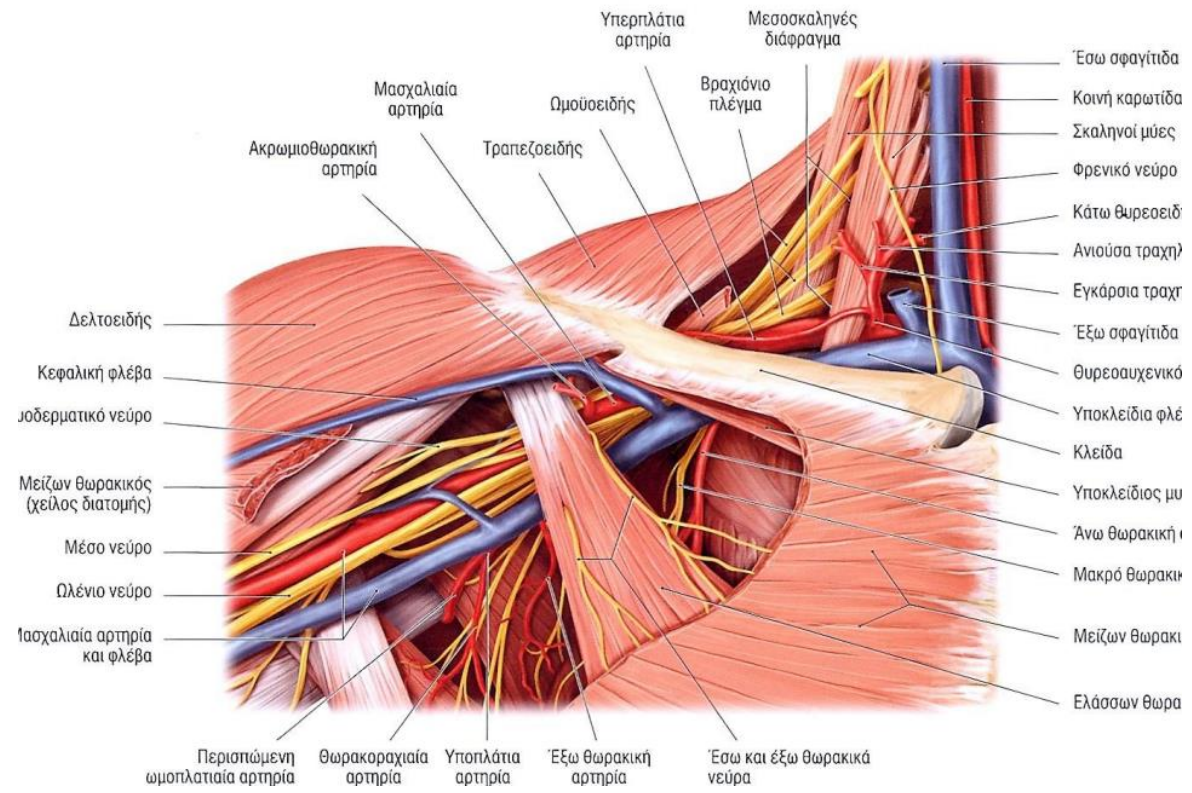
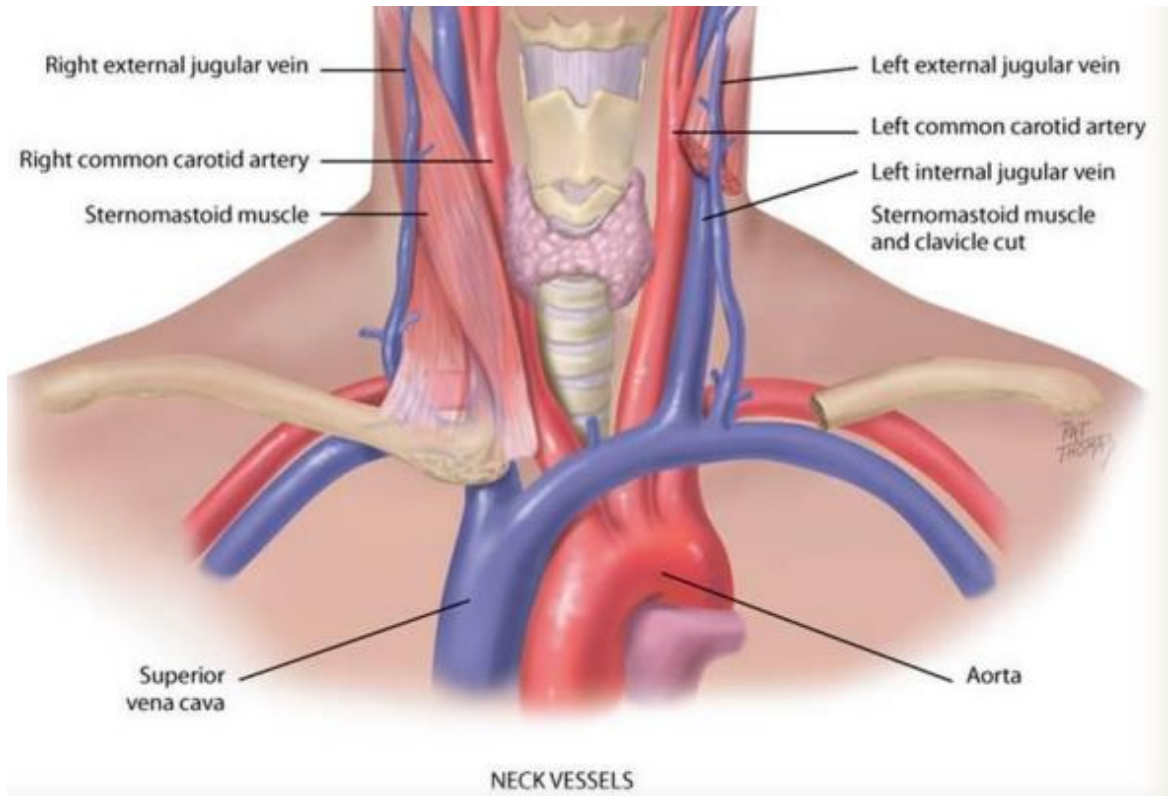
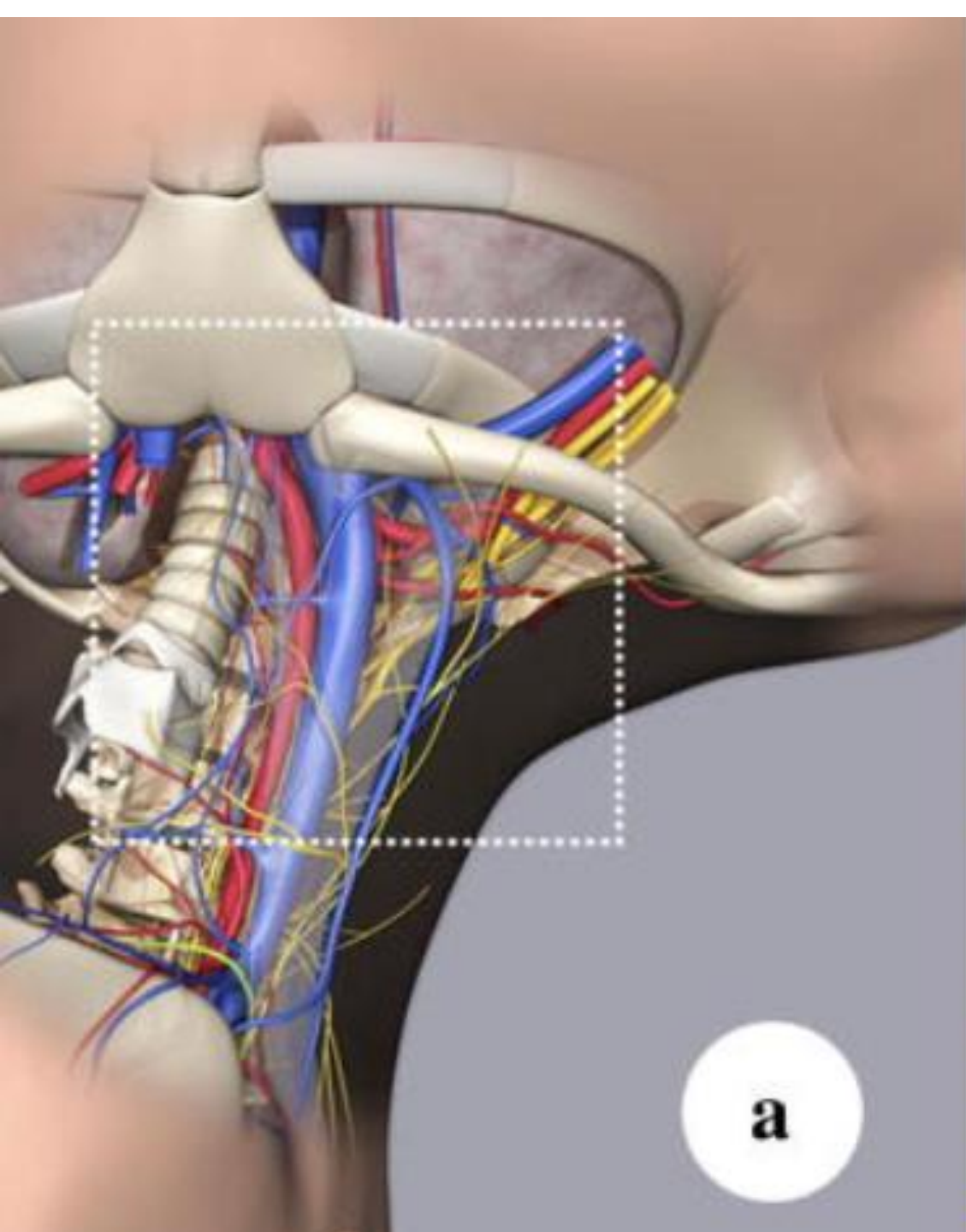
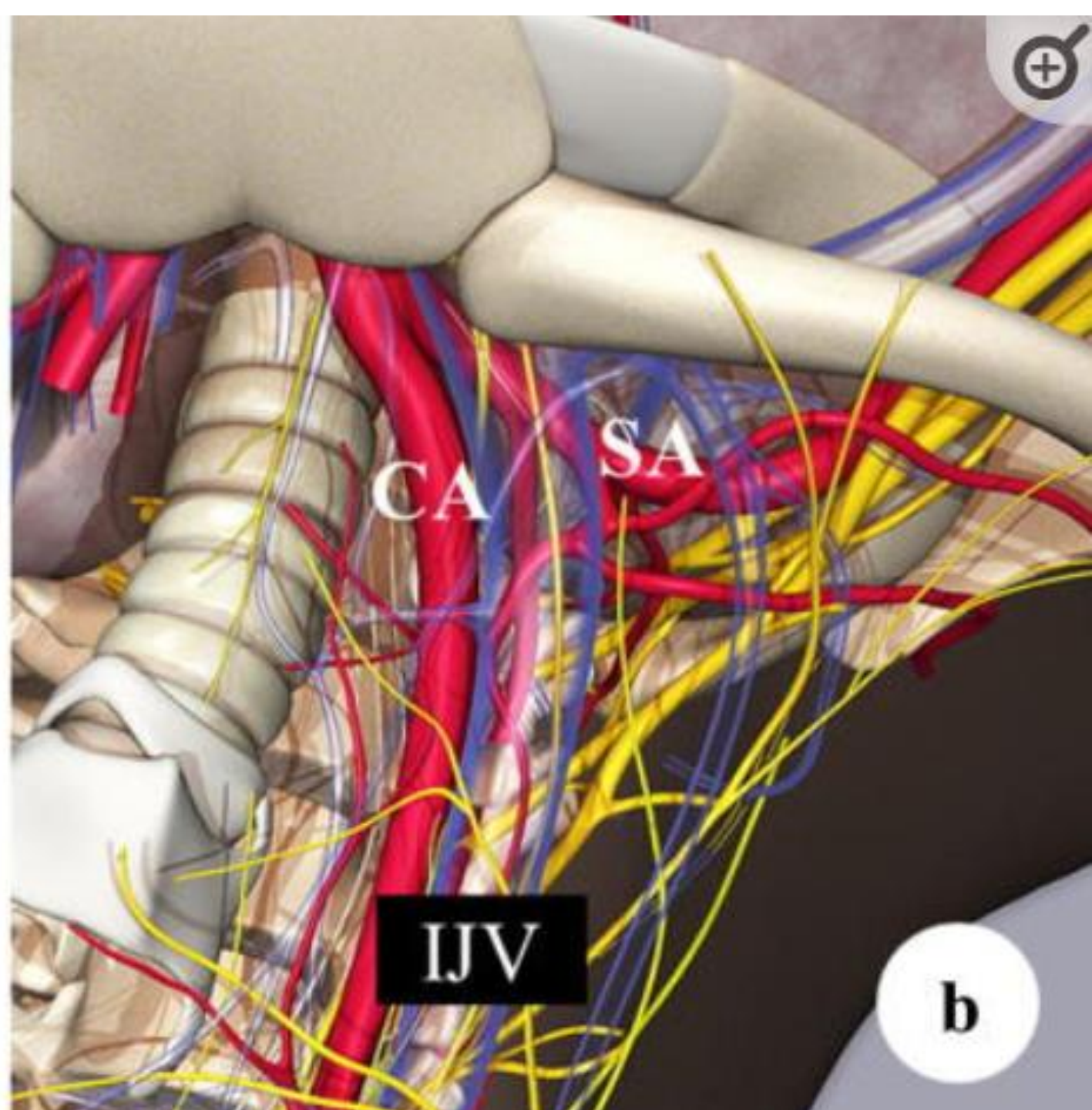


Figure 5 Sedillot's triangle: sternal head of sternocleidomastoid (yellow arrow), clavicular head sternocleidomastoid (orange arrow), clavicle (red arrow); and position of appropriate cutaneous puncture at apex of triangle (black star).

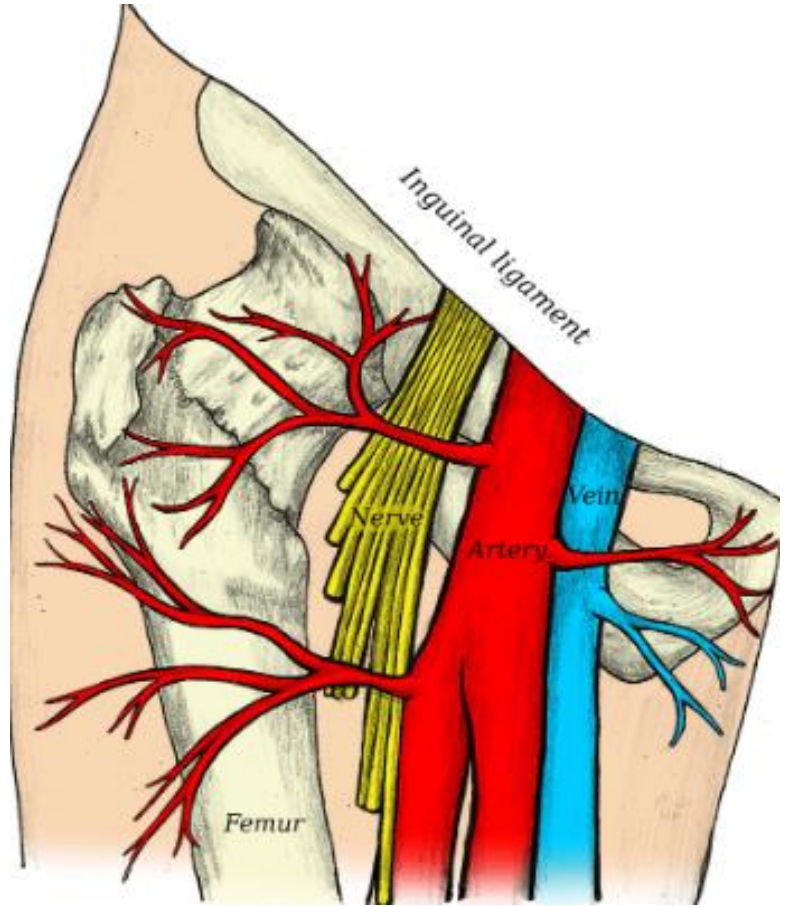
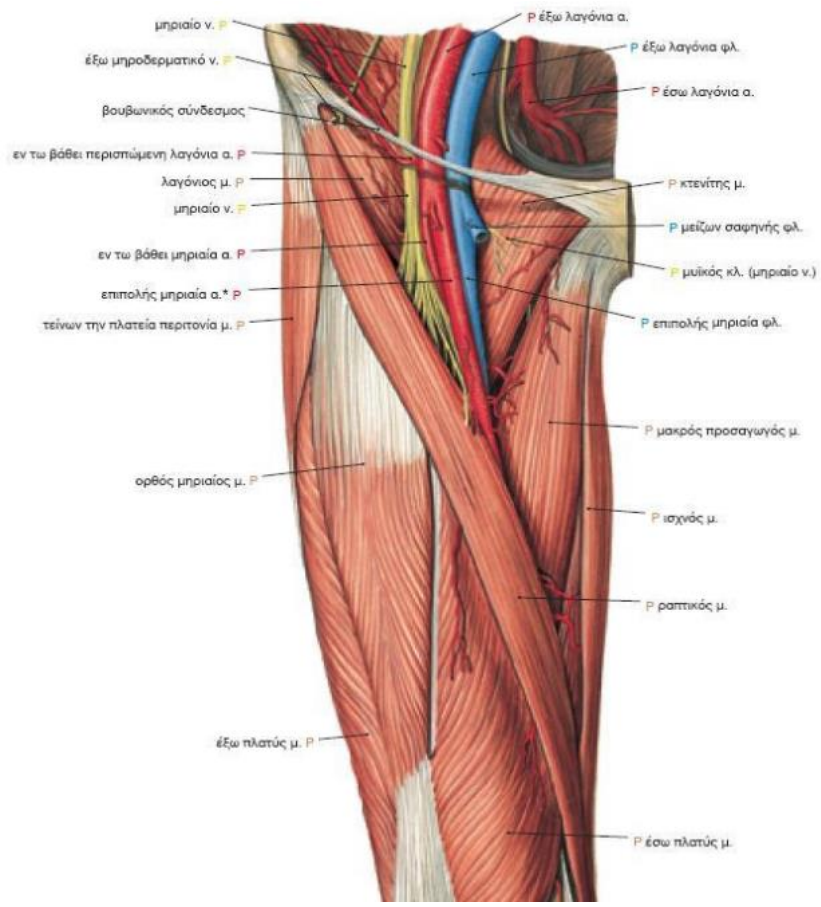




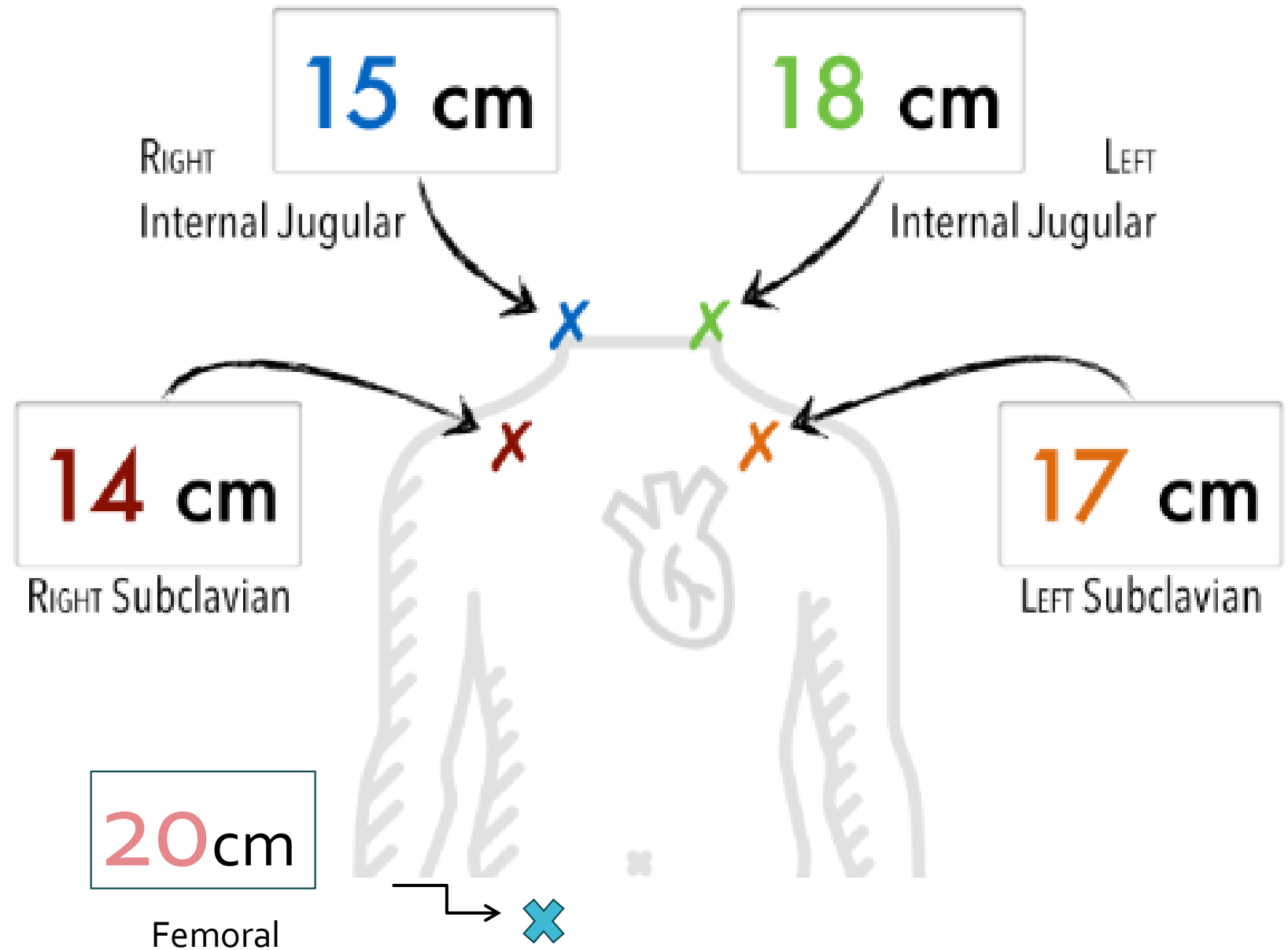
a



b



ΜΕΓΕΘΟΣ ΚΑΘΕΤΗΡΑ



ΔΙΑΔΙΚΑΣΙΑ

ΕΝΗΜΕΡΩΣΗ ΑΣΘΕΝΟΥΣ

ΕΝΥΠΟΓΡΑΦΗ ΣΥΓΚΑΤΑΘΕΣΗ

ΤΟΠΟΘΕΤΗΣΗ ΚΕΝΤΡΙΚΟΥ ΦΛΕΒΙΚΟΥ ΚΑΘΕΤΗΡΑ

ΕΛΕΓΧΟΣ ΘΕΣΗΣ ΚΕΝΤΡΙΚΟΥ ΦΛΕΒΙΚΟΥ ΚΑΘΕΤΗΡΑ

ΧΡΗΣΗ

ΥΛΙΚΑ

Ατομικός προστατευτικός εξοπλισμός(σκουφάκι, ποδιά, γάντια)

Γάζες

Επιθέματα χλωρεξιδίνης ή παρόμοιο αντισηπτικό μέσο

Αποστειρωμένο κάλυμμα μηχανήματος υπερήχων

Αποστειρωμένο πεδίο

ΚΦΚ (με τριπλό, διπλό ή μονό αυλό με ευρύ άνοιγμα)

Σύριγγες (5/10/20cc)

Νυστέρι με λεπίδα #11

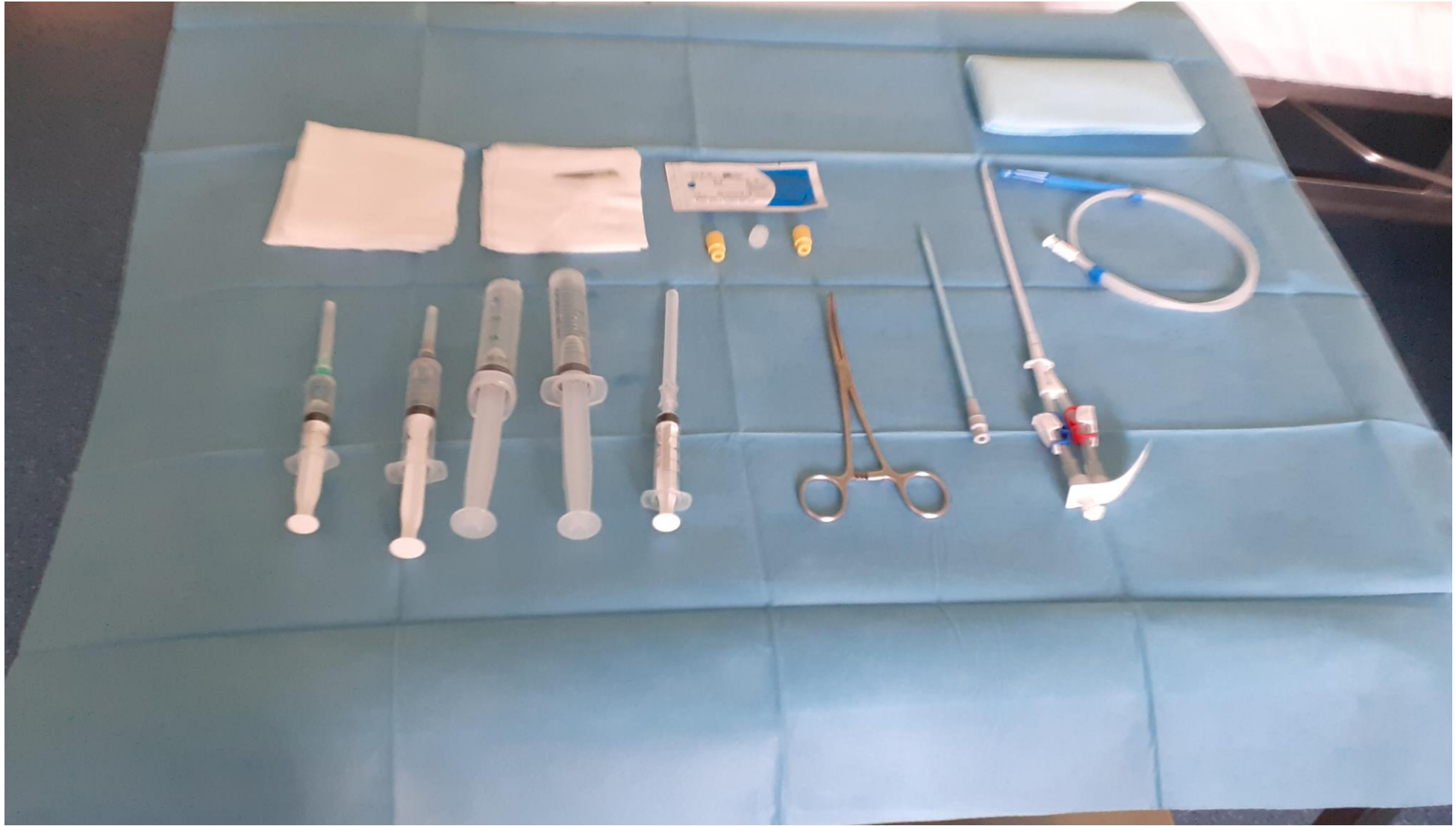
Συρμάτινος οδηγός

Φλεβοδιαστολέας

Σετ συρραφής ραμμάτων-Βελονοκάτοχος-λαβίδα

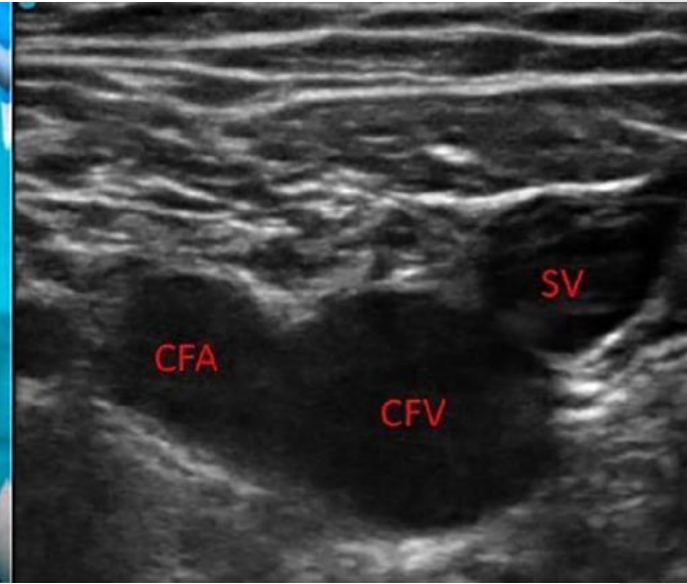
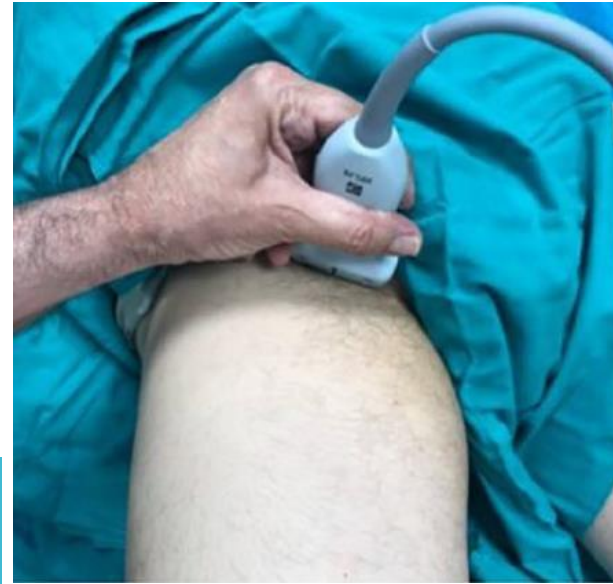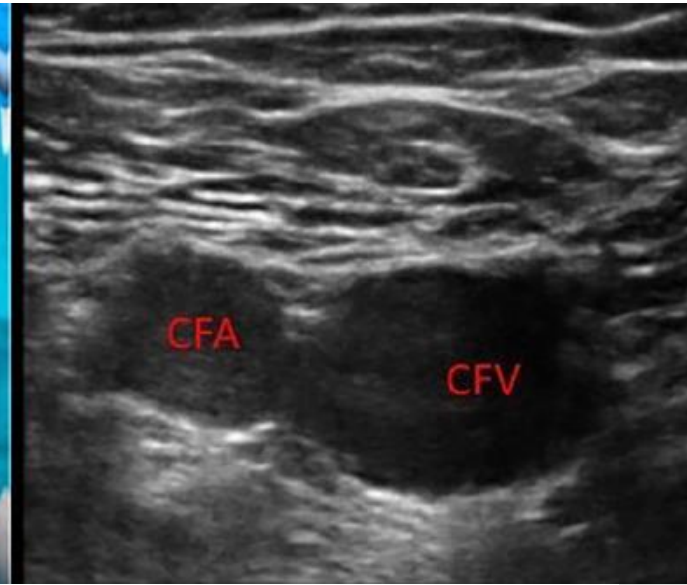
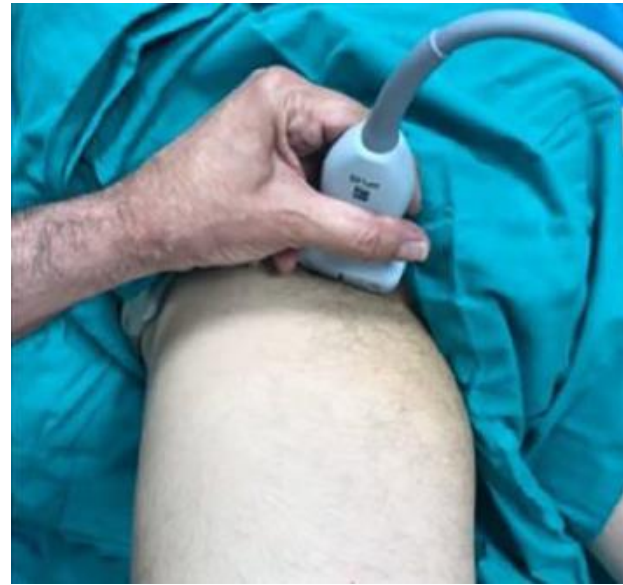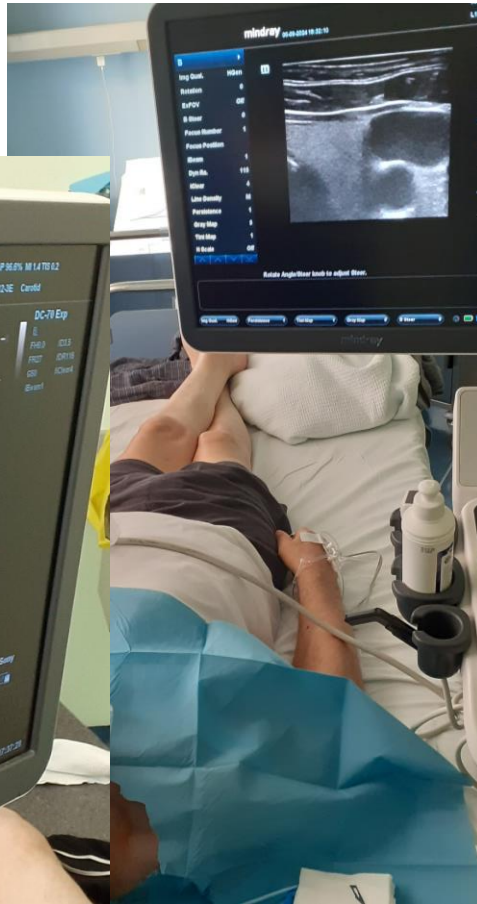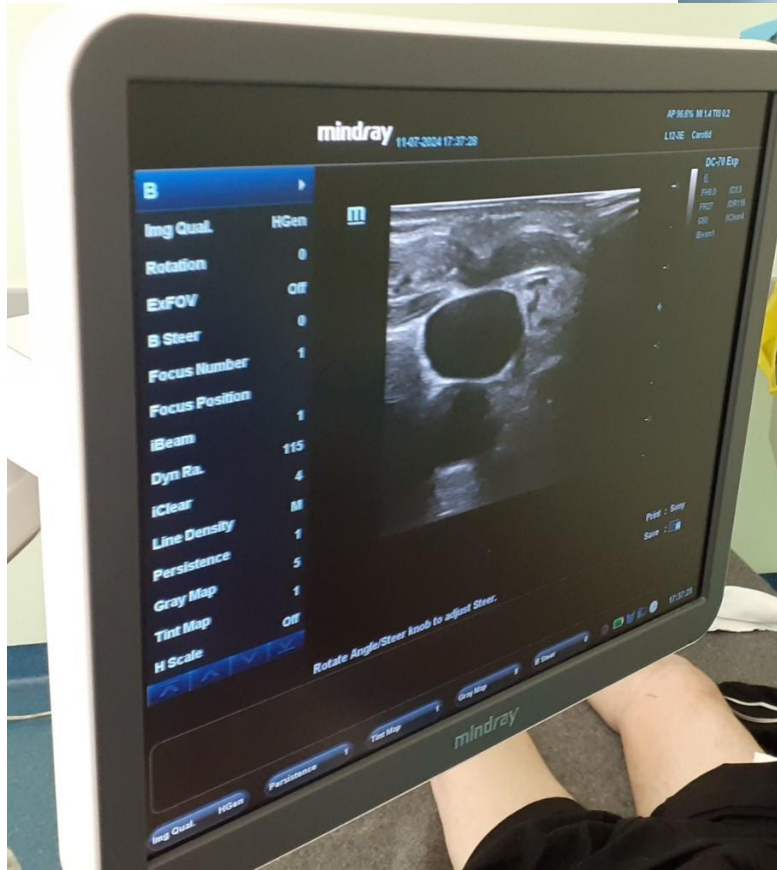
Φυσιολογικός ορός

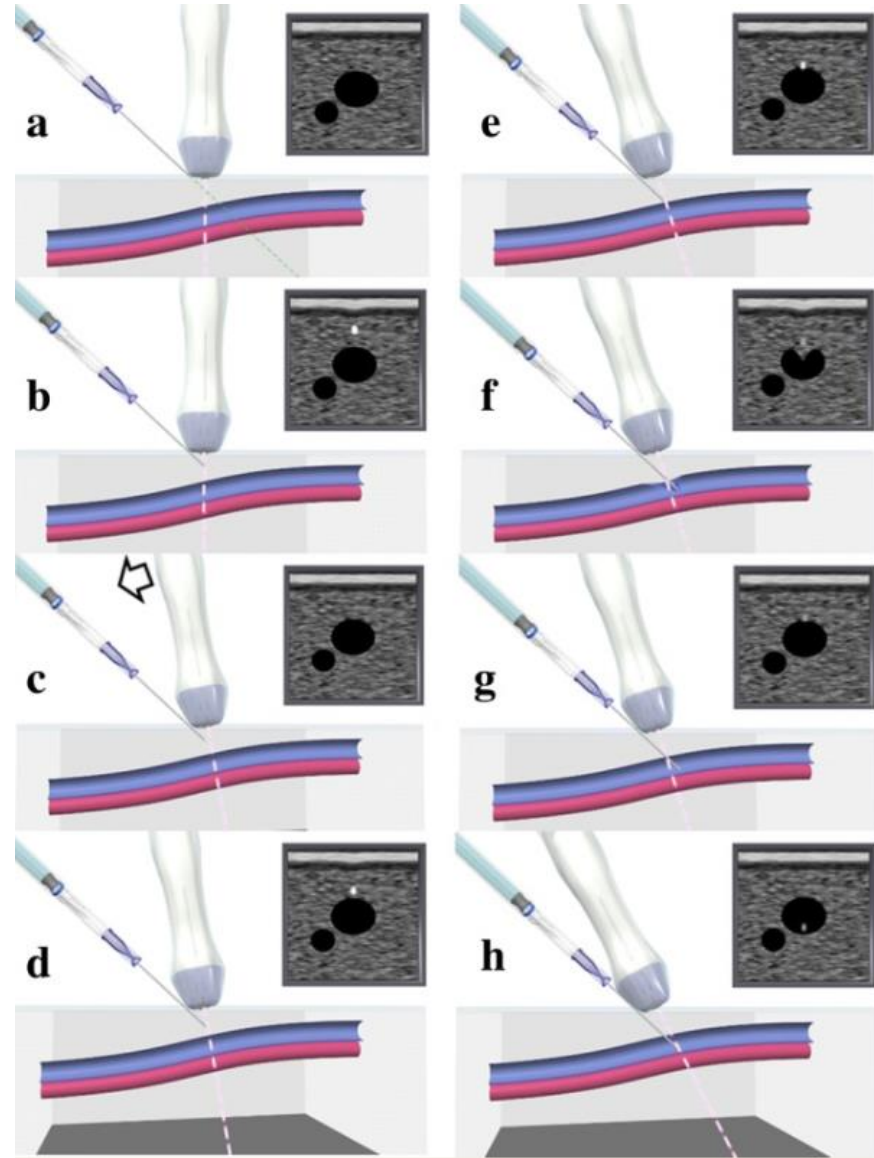
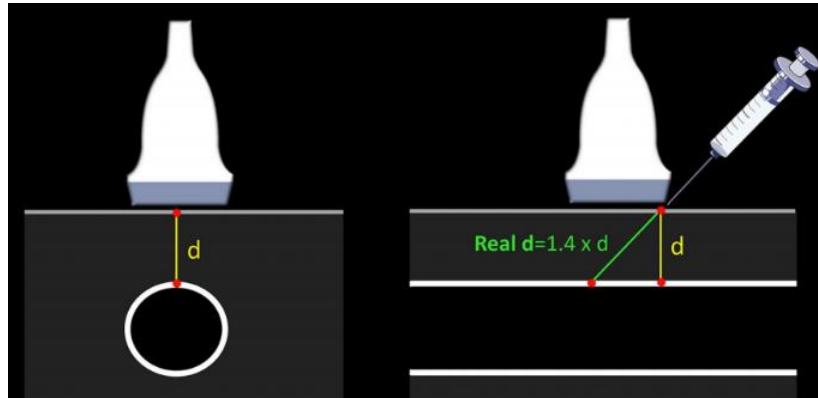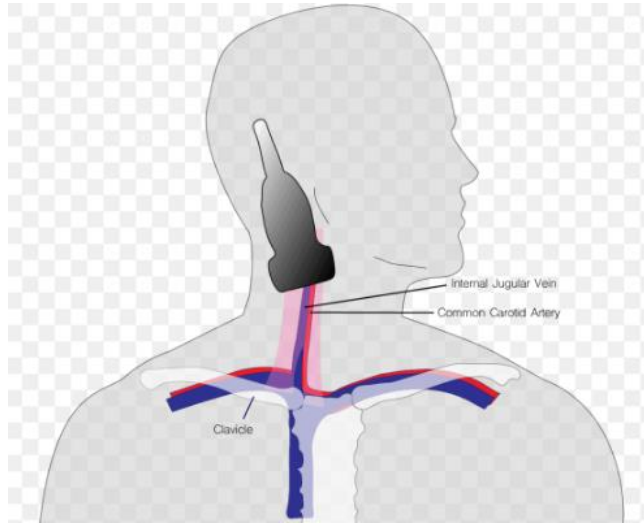
Λιδοκαΐνη 1%, βελόνα μικρού διαμετρήματος



ΥΠΕΡΗΧΟΓΡΑΦΙΚΟΣ ΕΛΕΓΧΟΣ

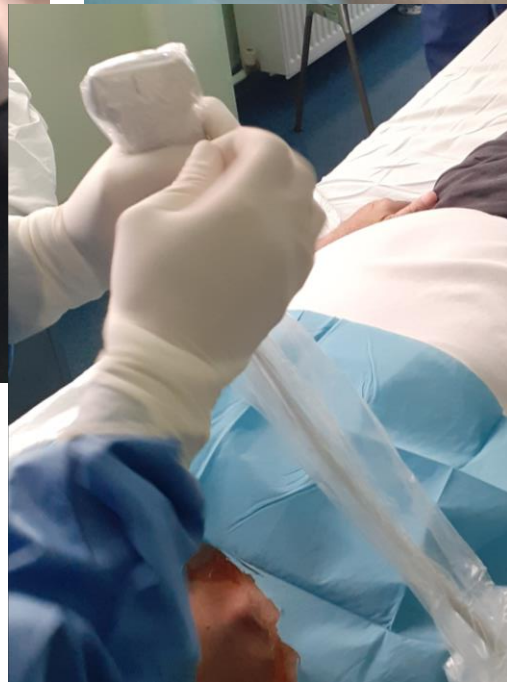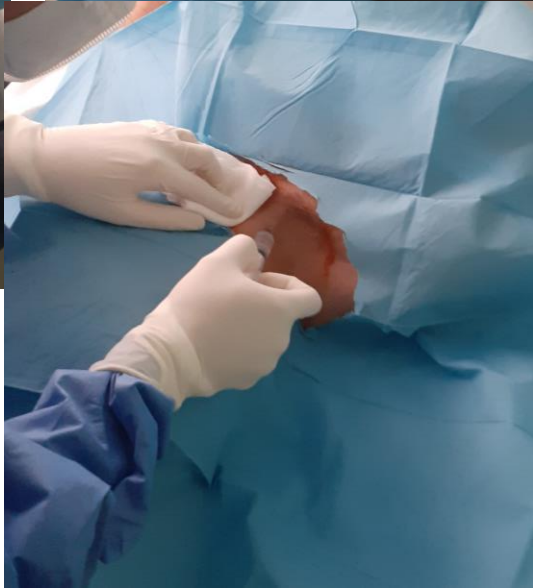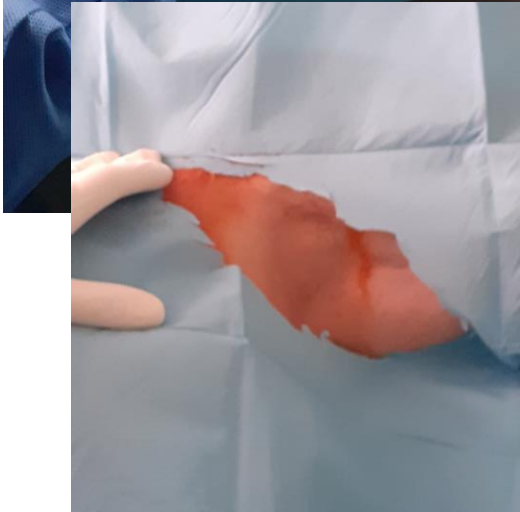
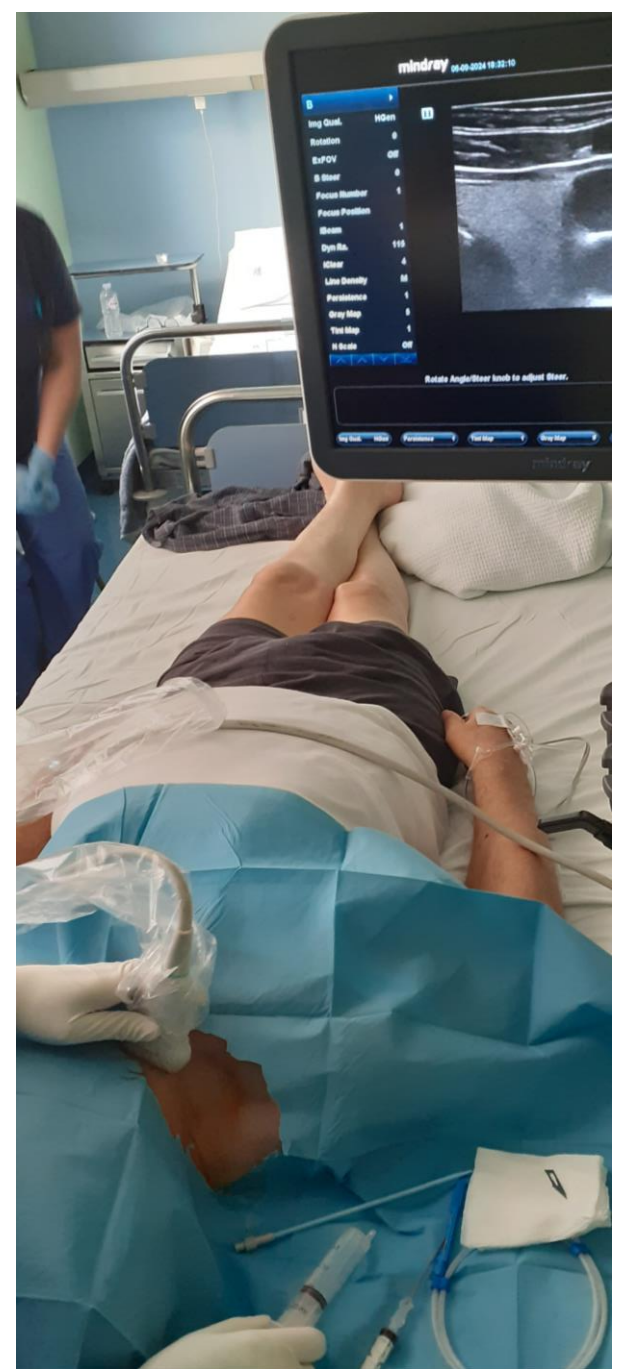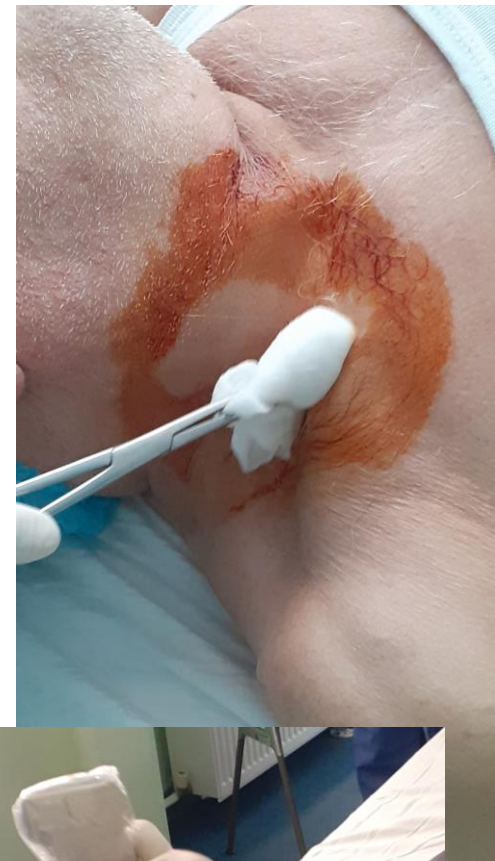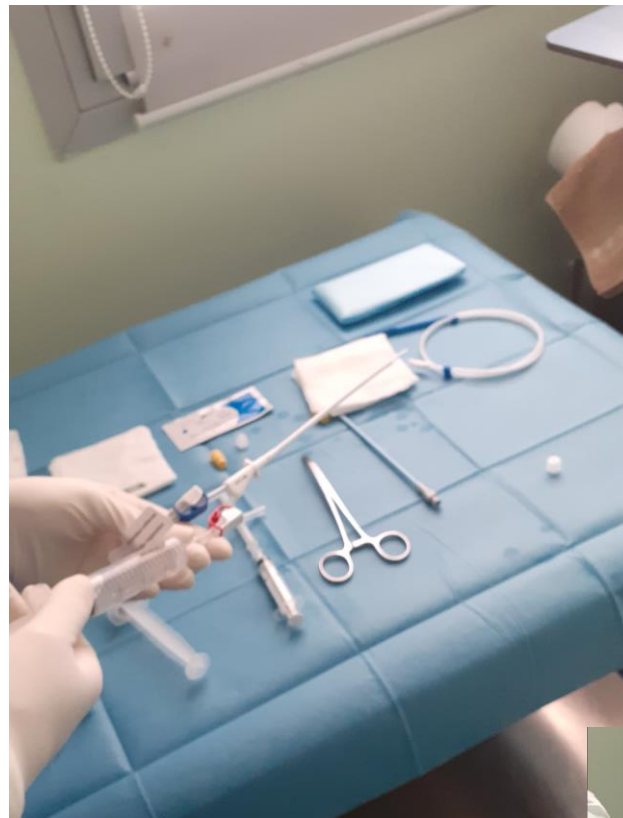




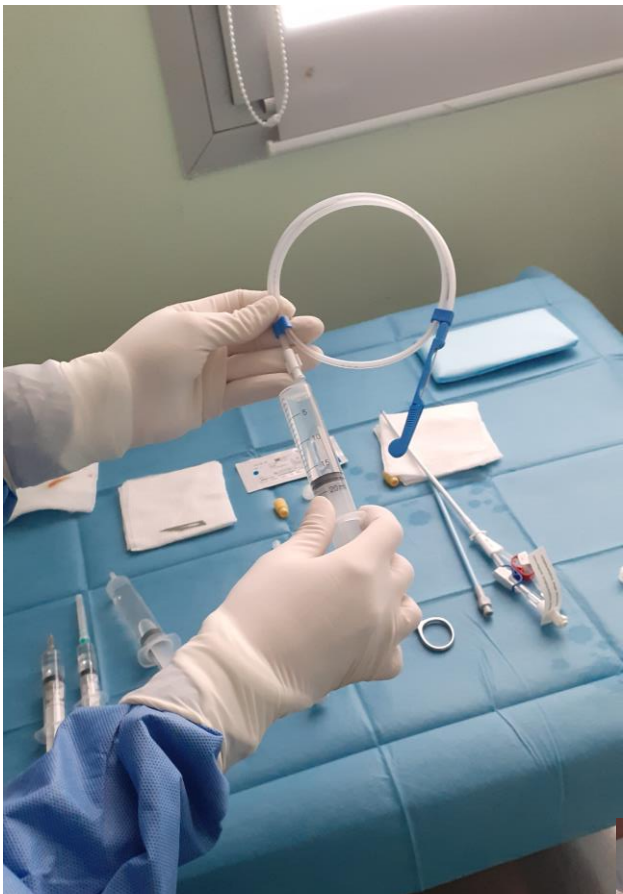

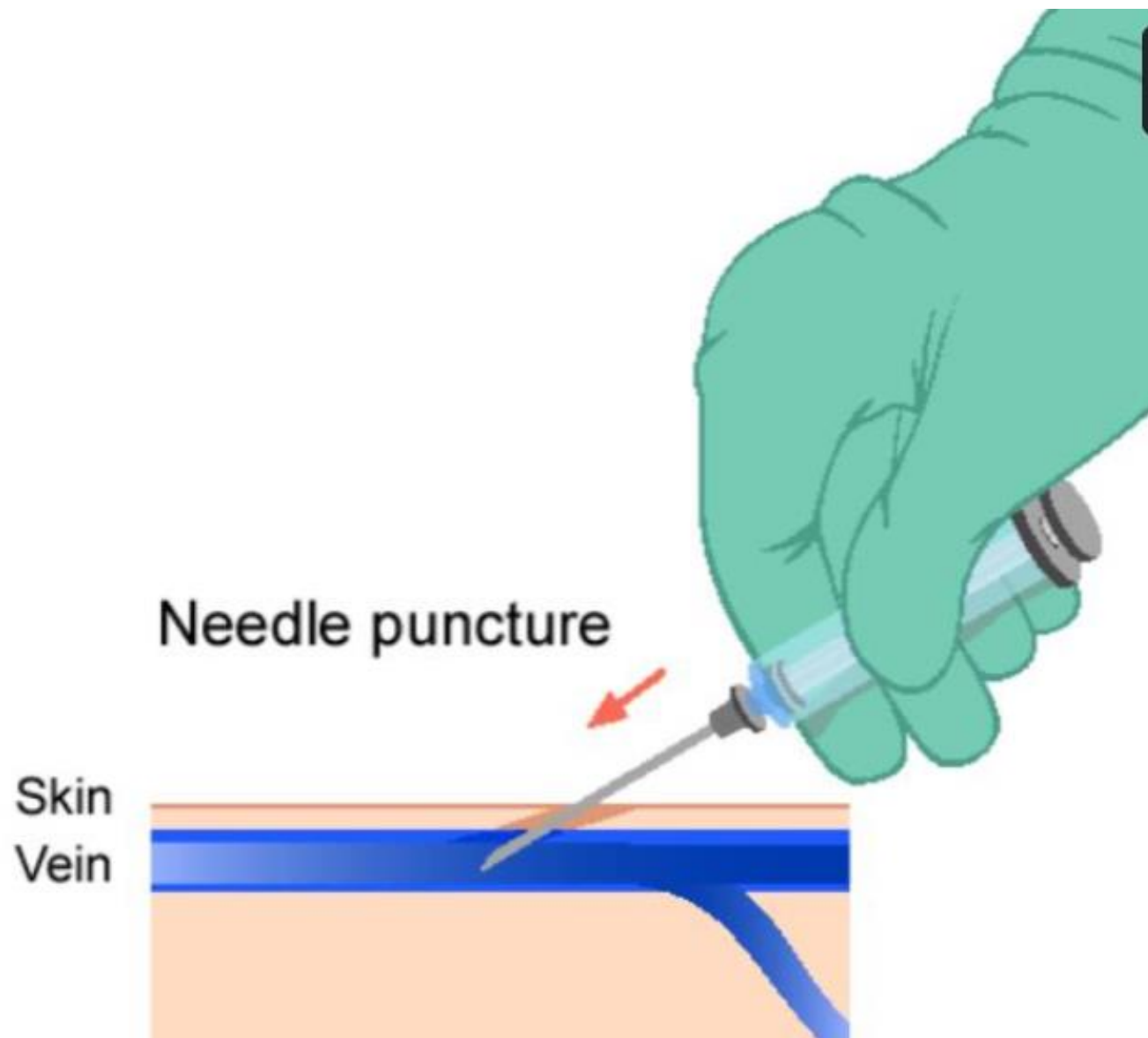
The image features a white background with two large teal geometric shapes. On the left, a teal triangle points towards the center. On the right, a teal trapezoid is positioned. The word 'ΠΡΟΕΤΟΙΜΑΣΙΑ' is centered between these shapes in a teal, sans-serif font.

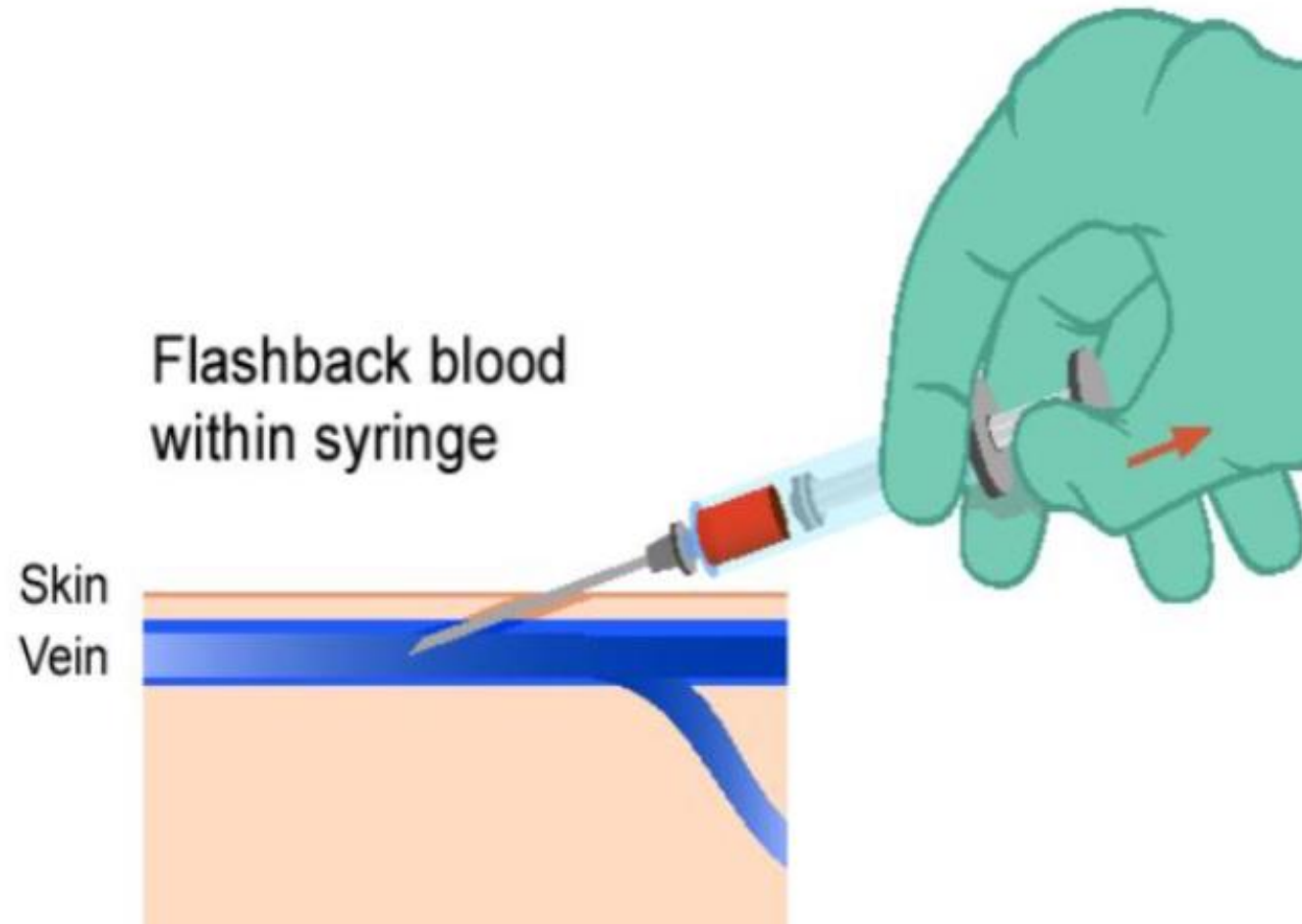
ΠΡΟΕΤΟΙΜΑΣΙΑ



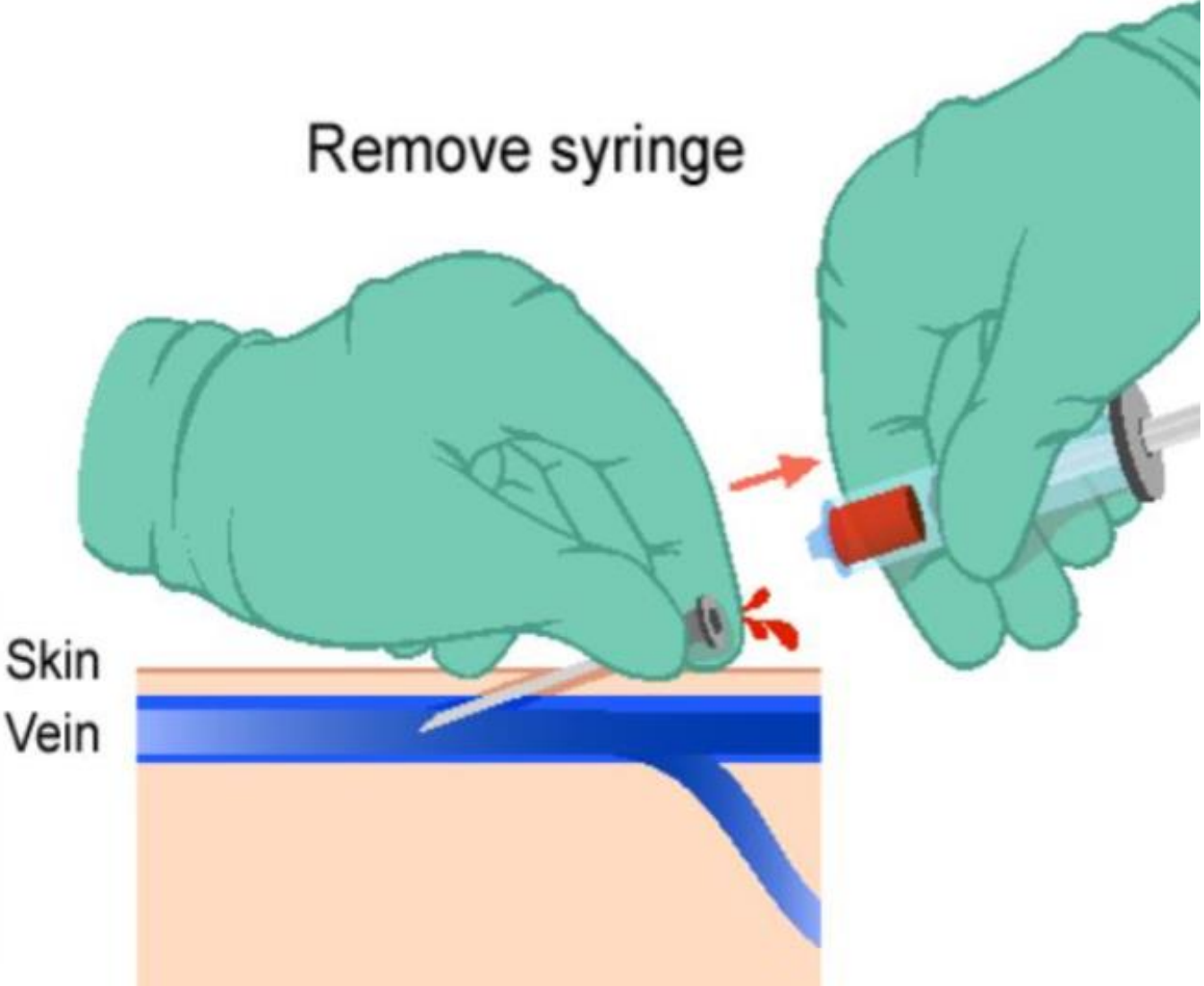
The image features a white background with two large teal geometric shapes. On the left, a teal triangle points towards the center. On the right, a teal trapezoid is positioned. The text 'TEXNIKH SELDINGER' is centered between these shapes.

TEXNIKH SELDINGER

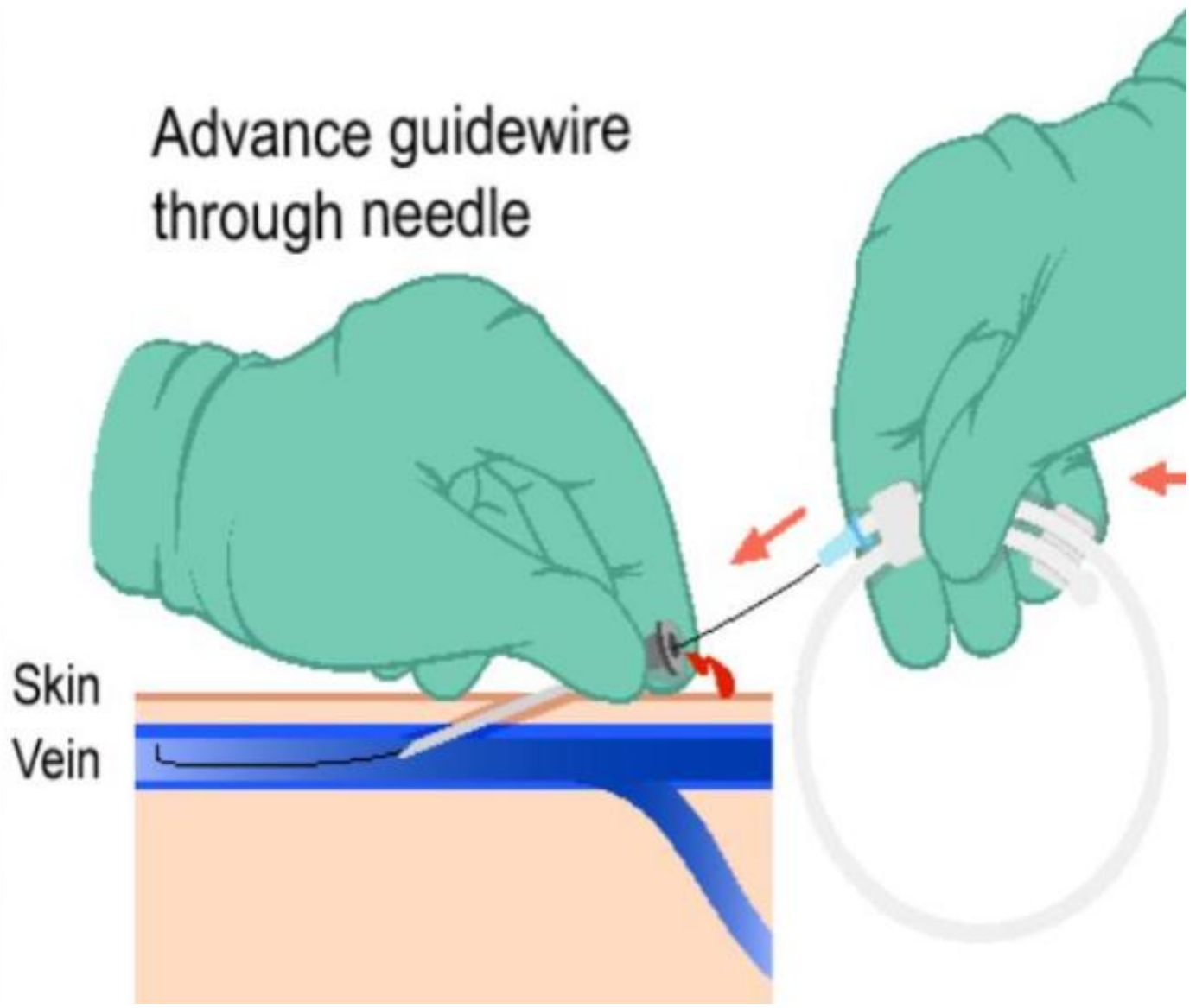




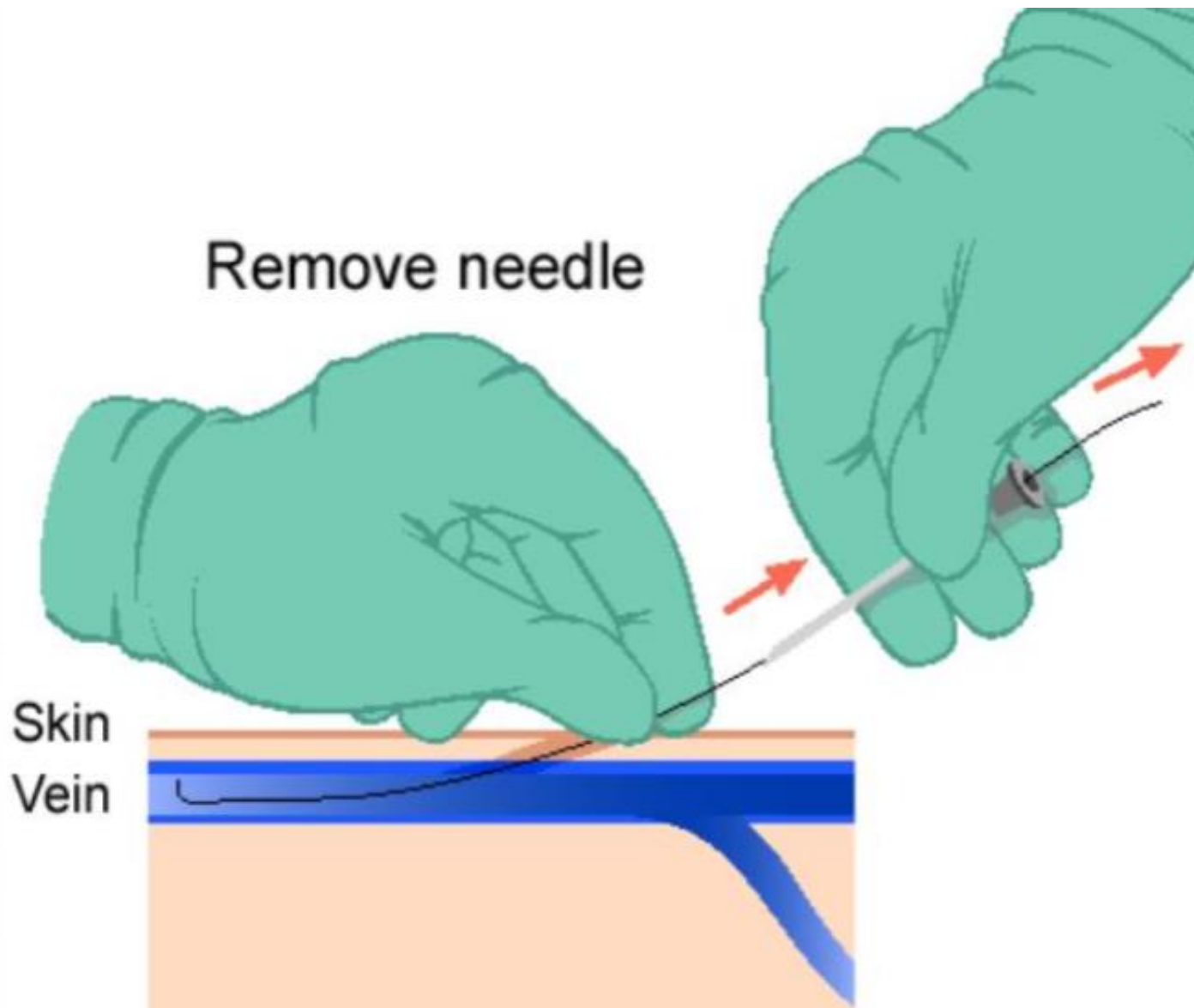
Remove syringe

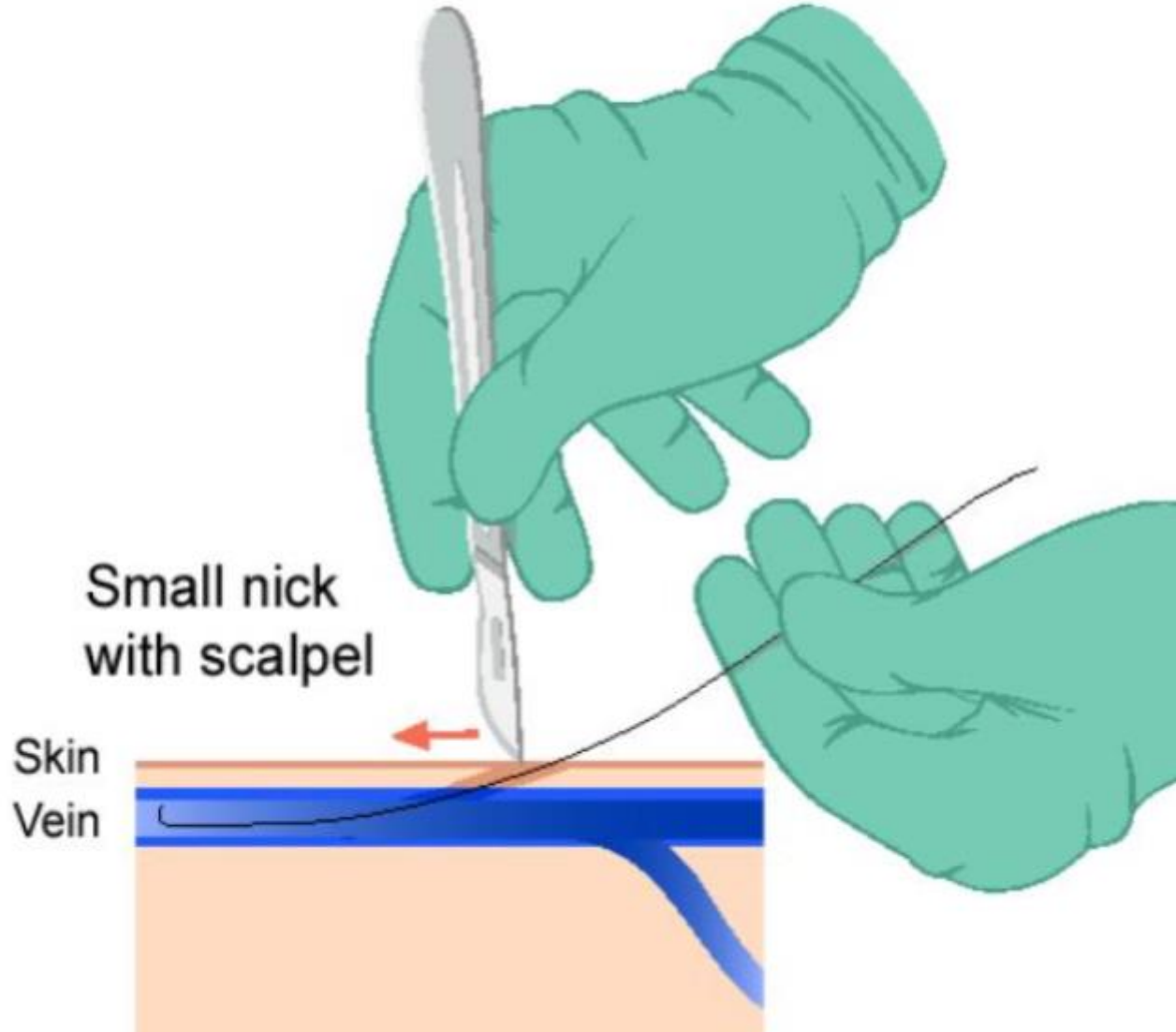


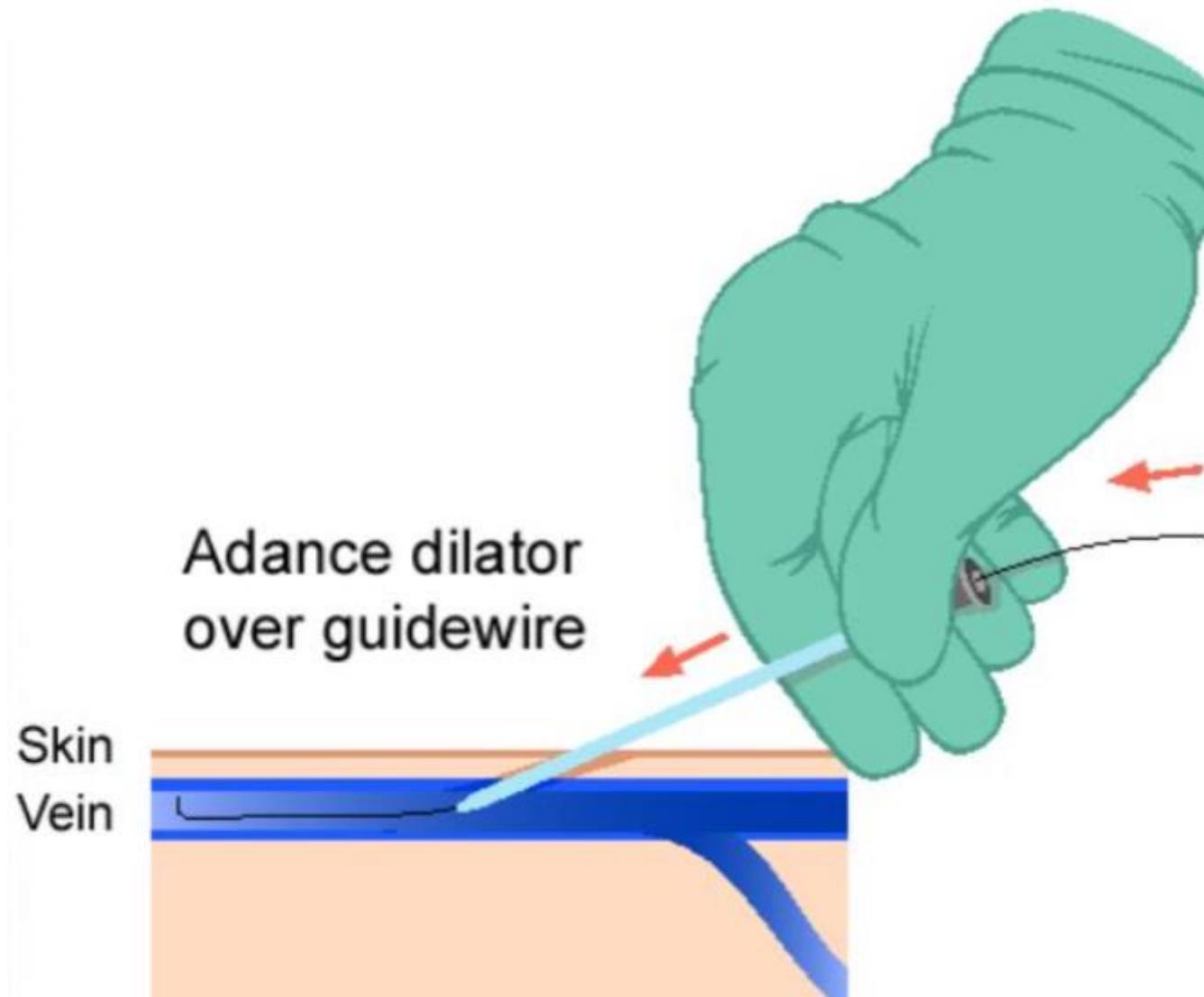
Advance guidewire through needle

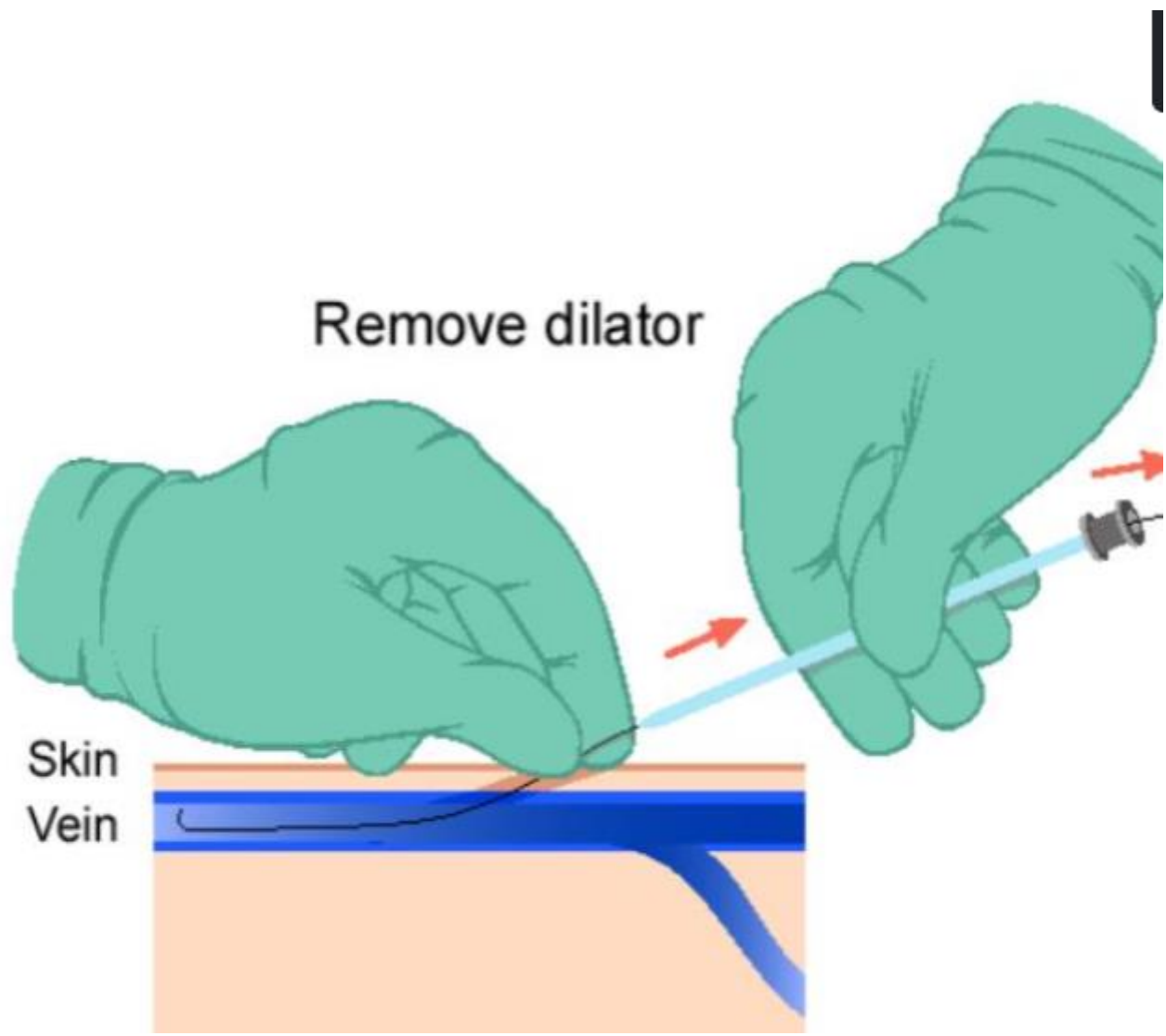


Skin
Vein



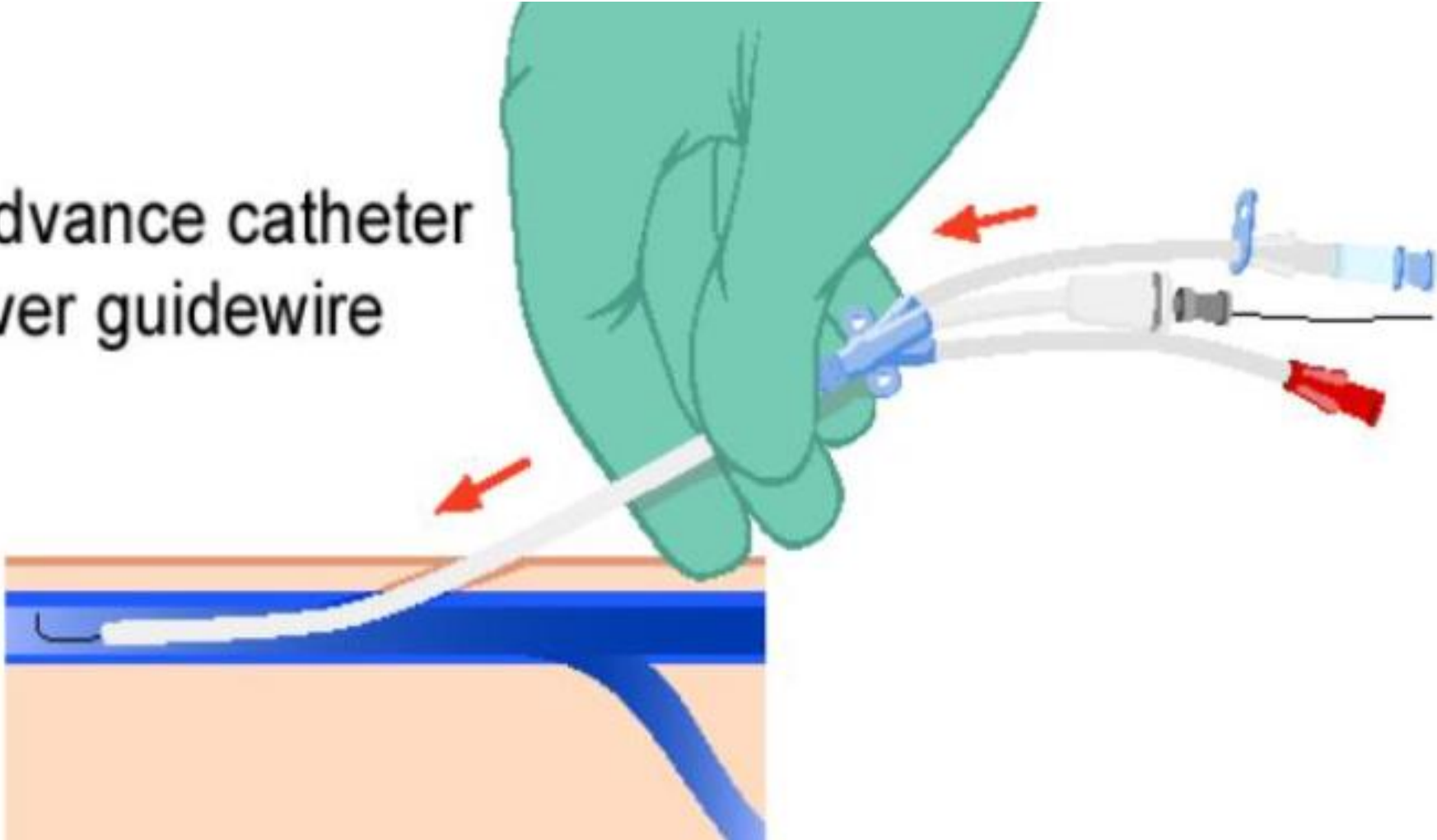




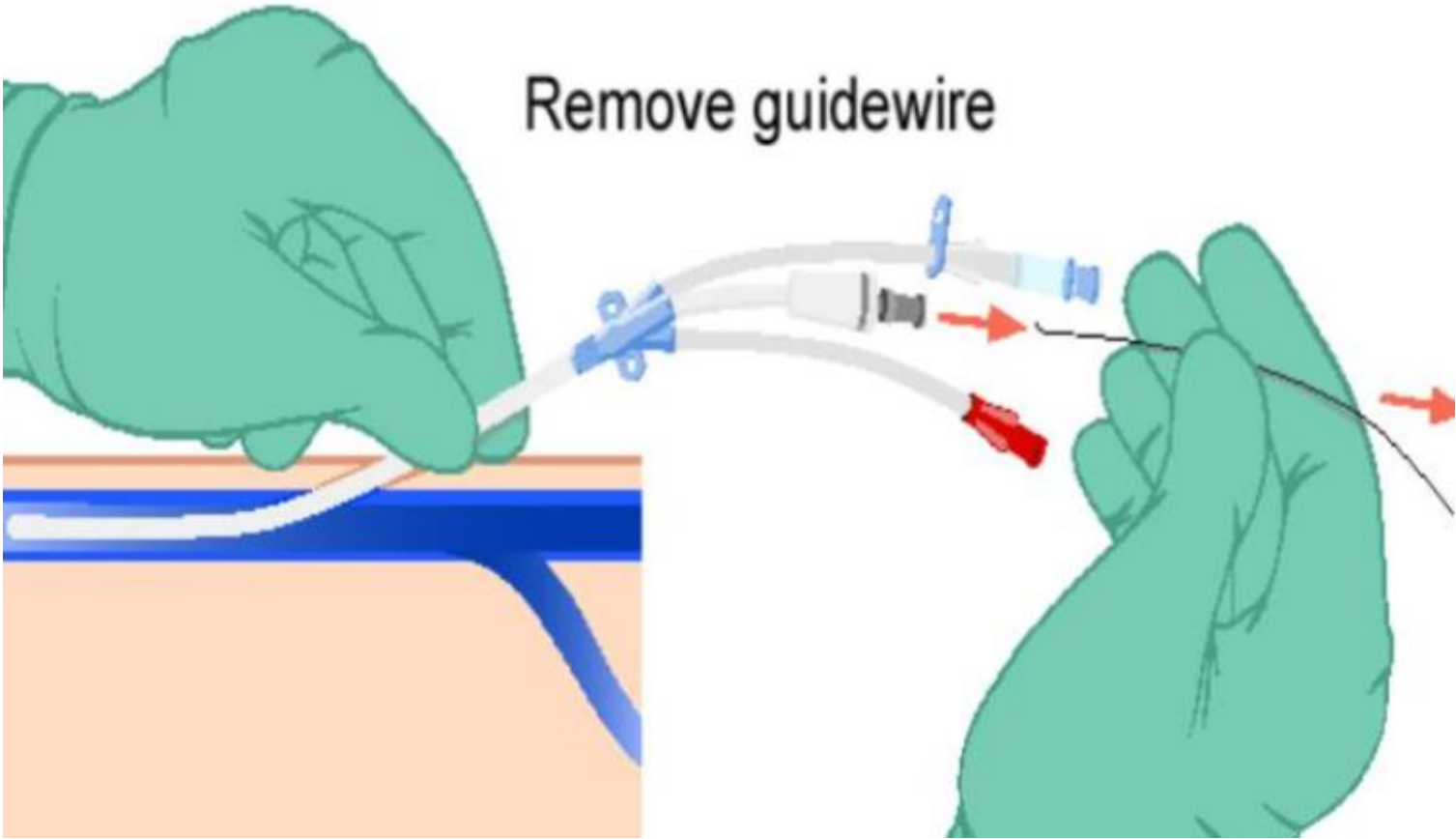


Advance catheter
over guidewire

Skin
Vein

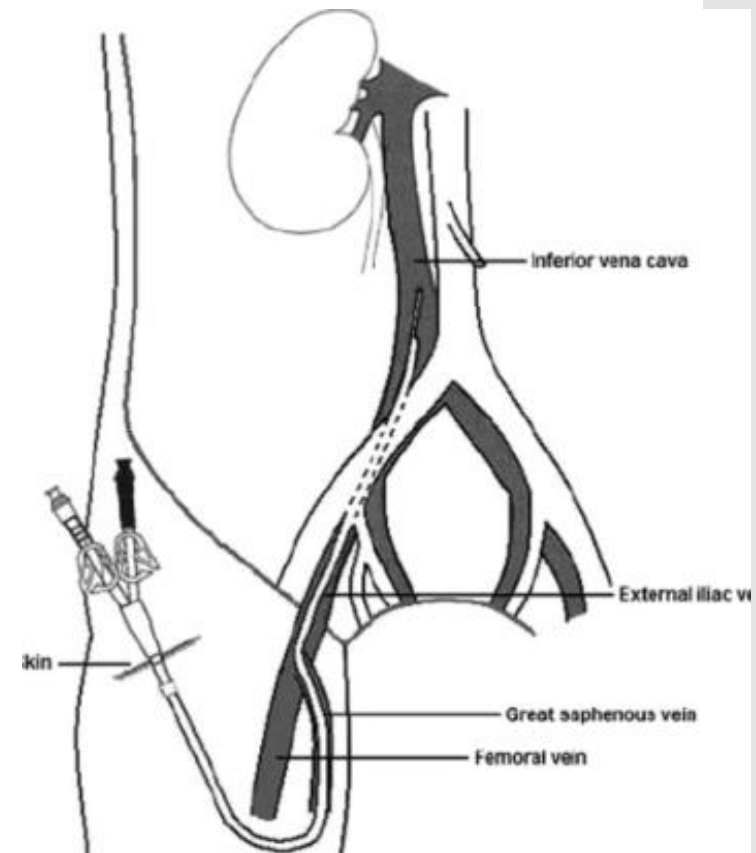
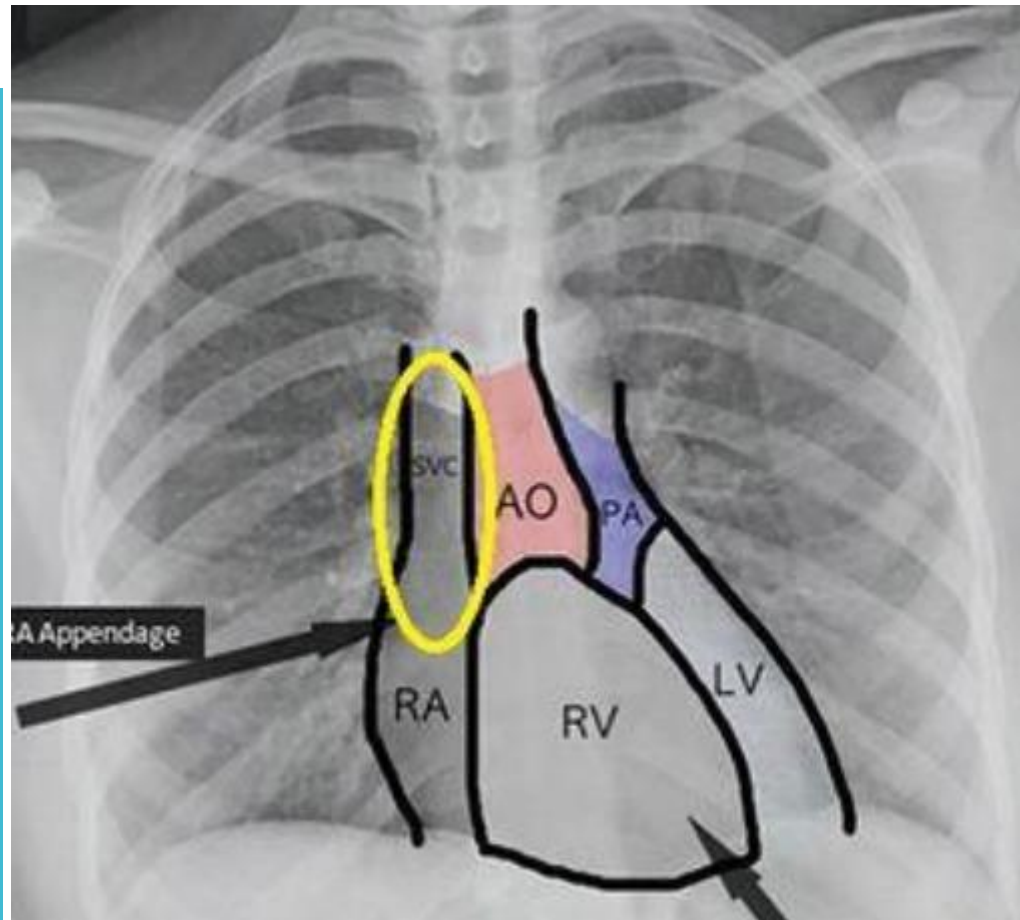


Remove guidewire



ΠΡΟΒΟΛΗ ΒΙΝΤΕΟ

ΕΛΕΓΧΟΣ ΘΕΣΗΣ ΚΦΚ



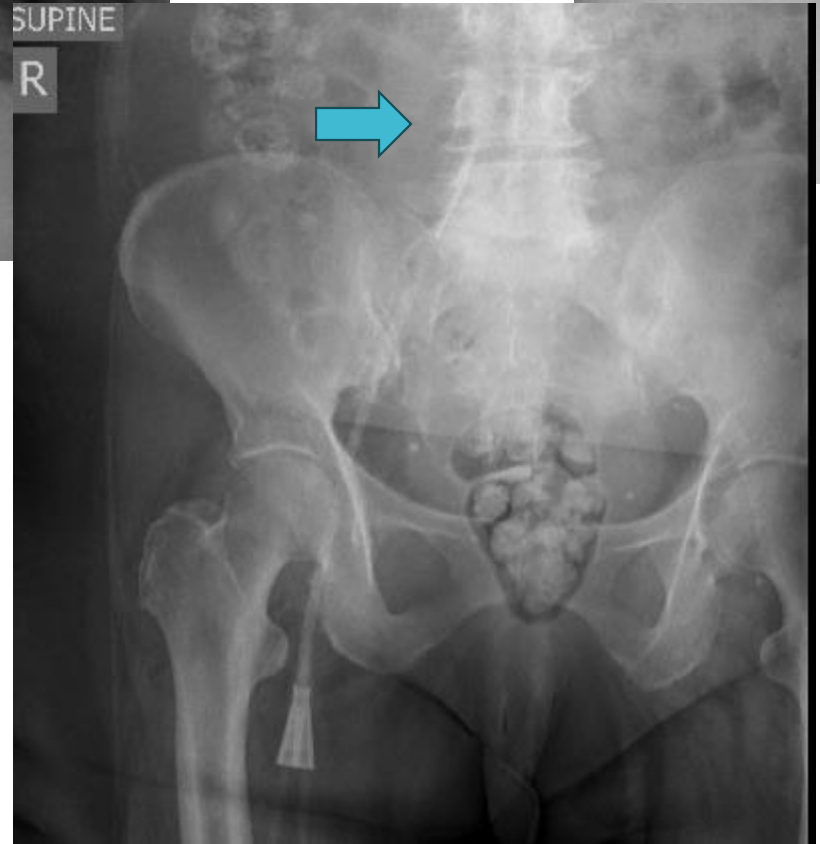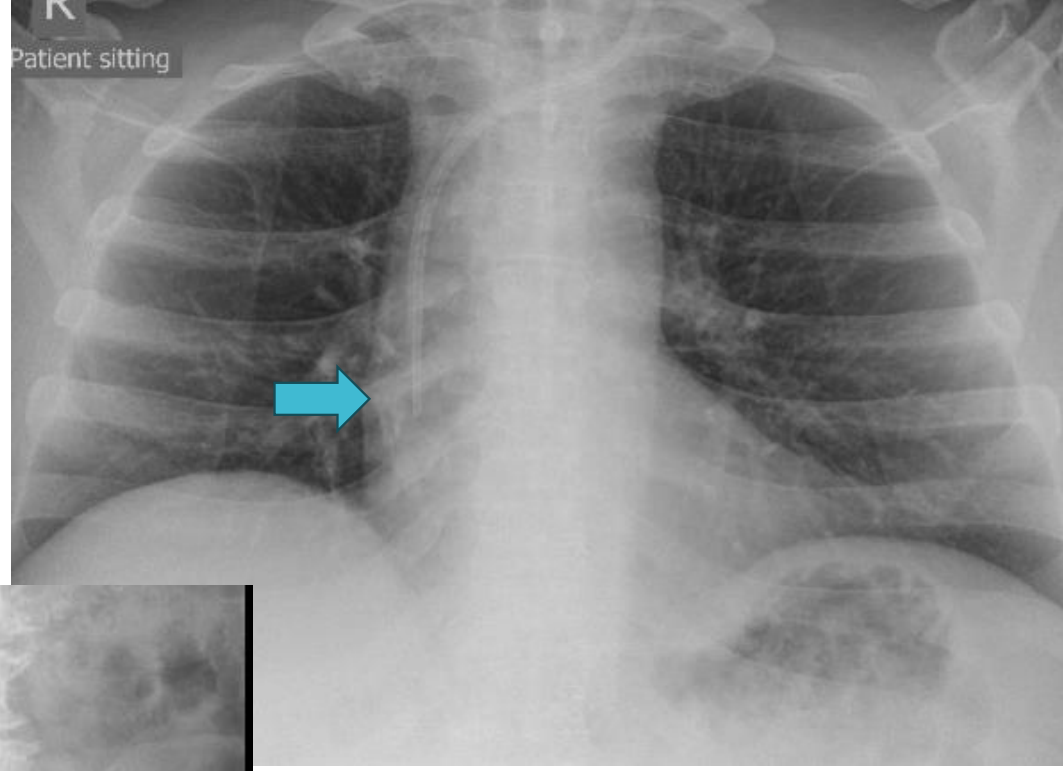
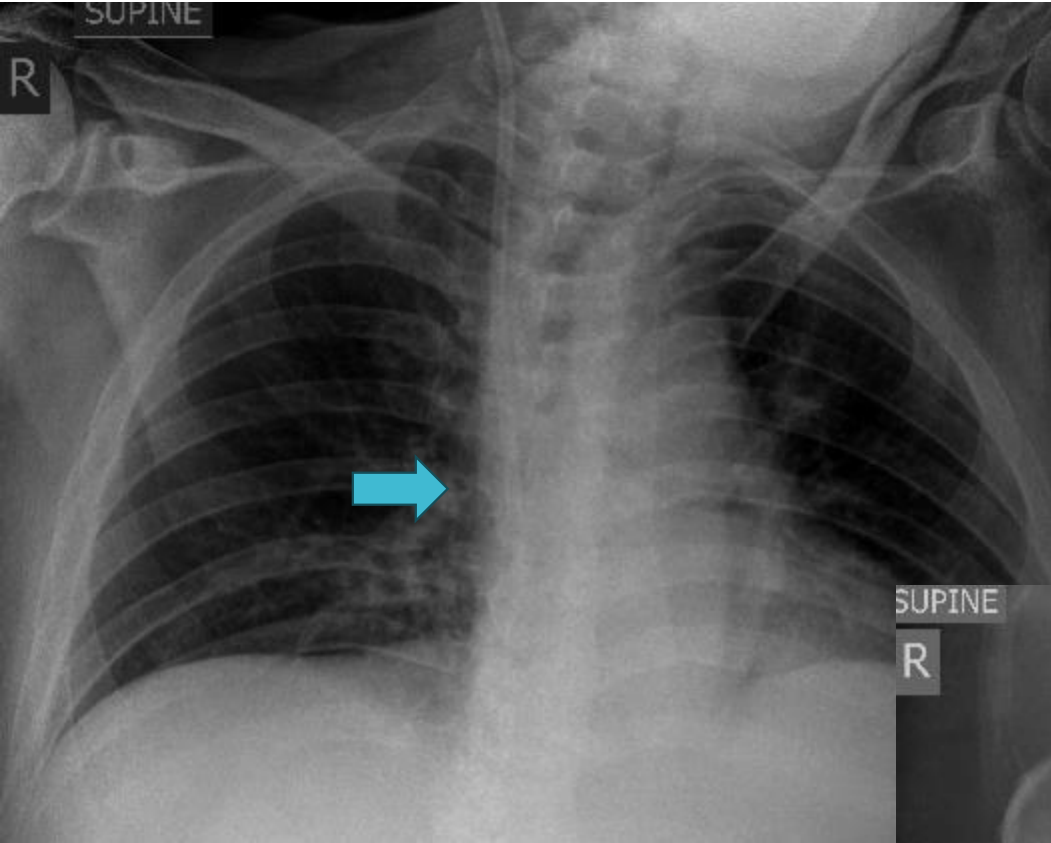


TABLE 7.2 Complications of Central Venous Catheterization

Immediate Complications

- Arterial puncture (all)
- Pneumothorax (IJ, SC)
- Hemothorax (IJ, SC)
- Arrhythmias (IJ, SC)
- Air embolism (all IJ, SC >> F)
- Perforation of cardiac chamber (IJ, SC)
- Pericardial tamponade (IJ, SC)
- Retroperitoneal hemorrhage (F)

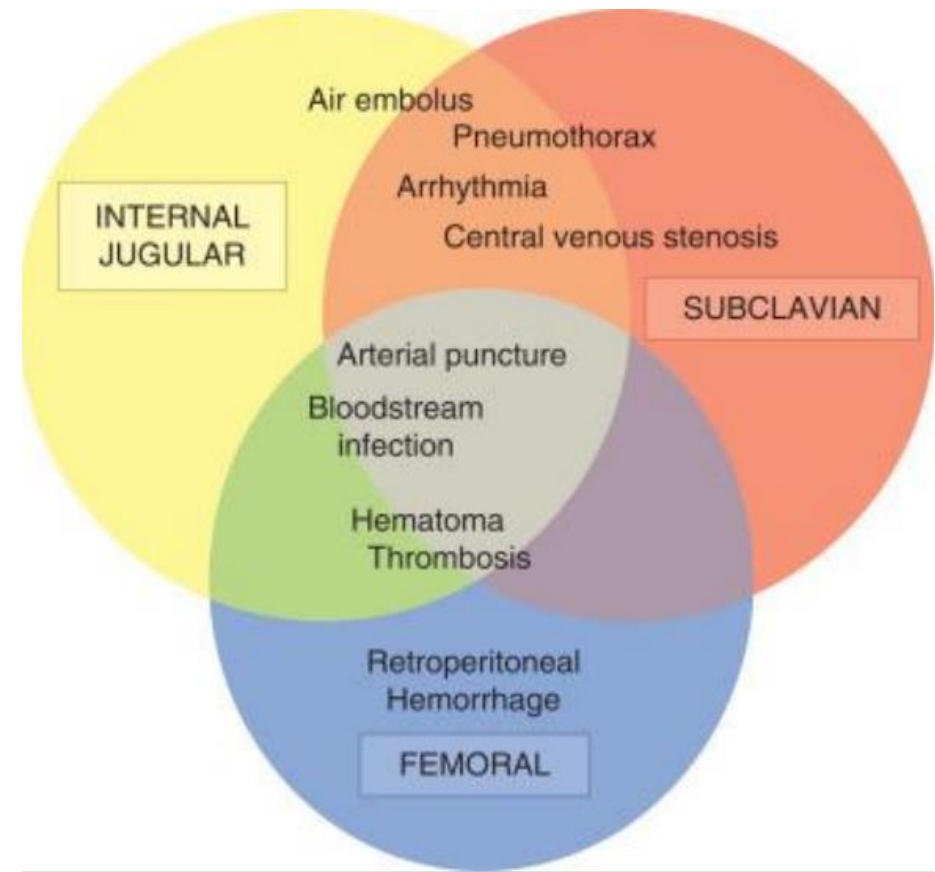
Delayed Complications

- Thrombosis (all)
- Infection (all)
- Central venous stenosis (SC >> IJ)
- Arteriovenous fistula (all)

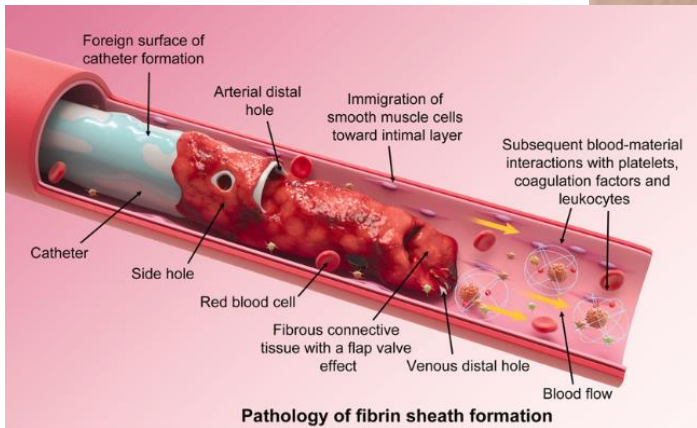
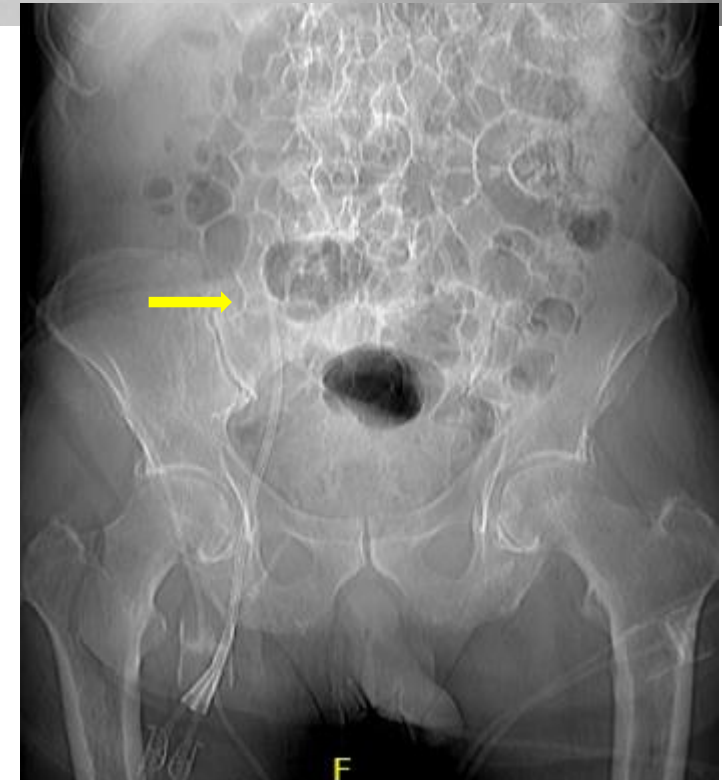
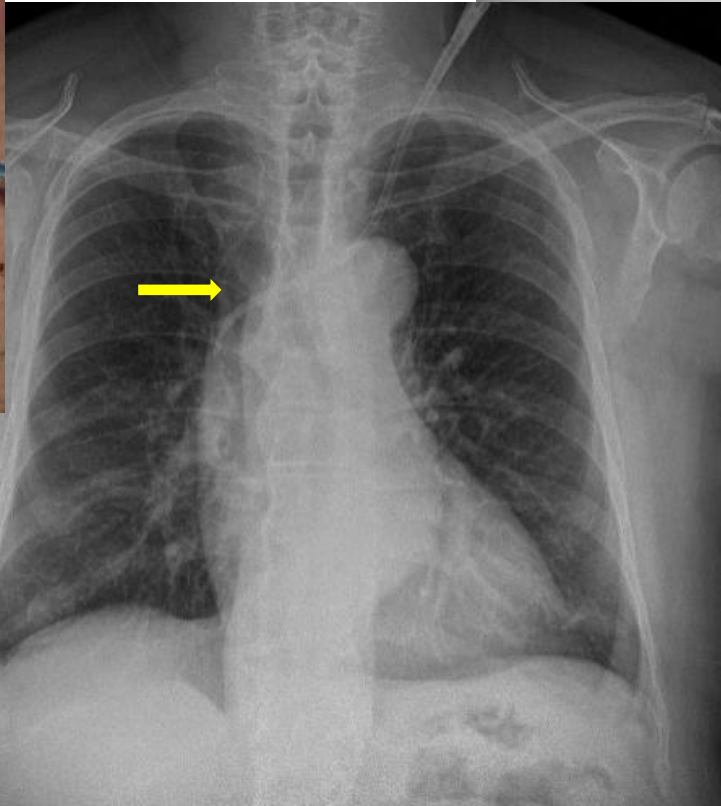
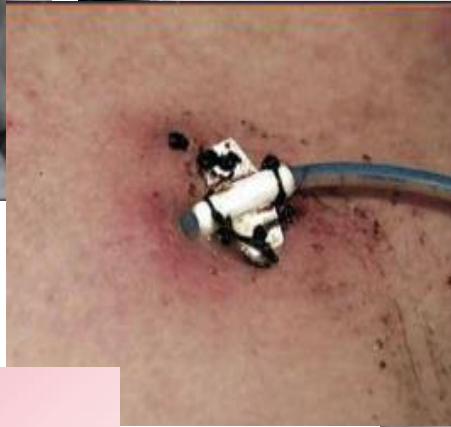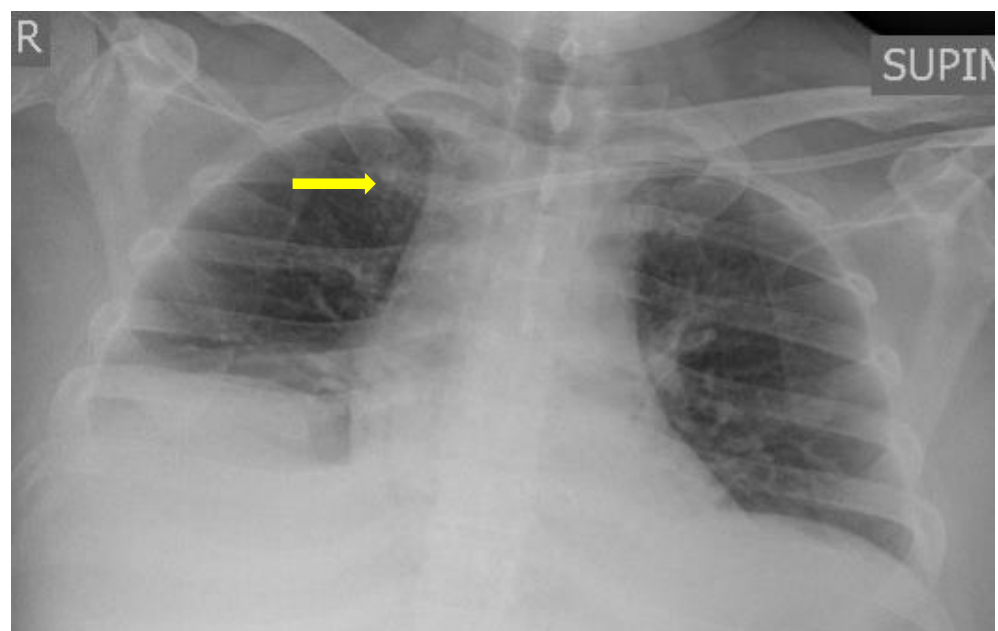
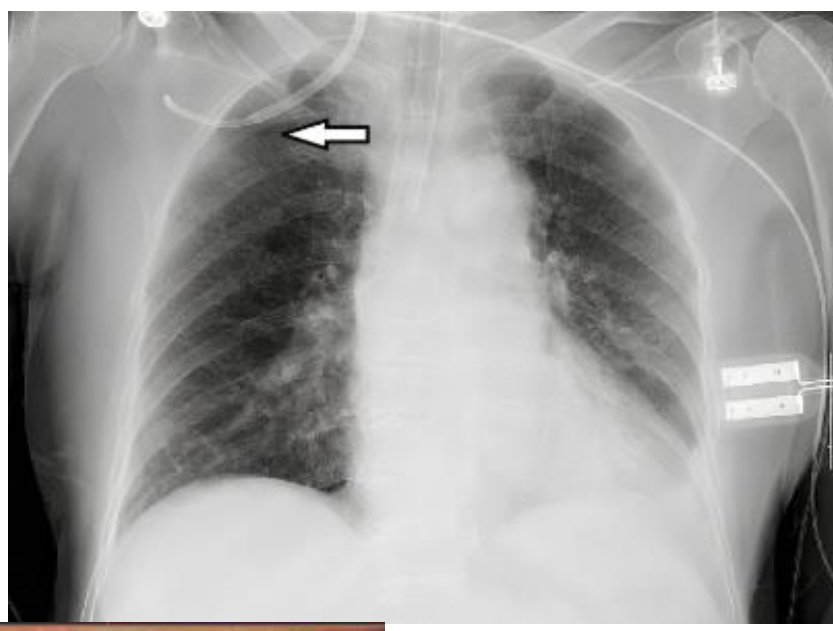
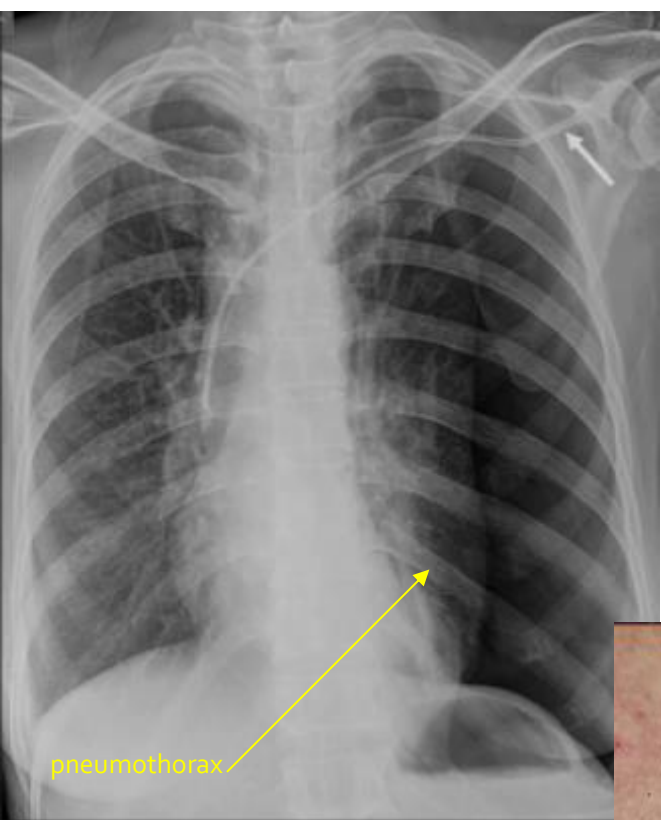
Injury to Adjacent Structures

- Brachial plexus (IJ, SC)
- Recurrent laryngeal nerve (IJ, SC)

IJ, internal jugular; SC, subclavian; F, femoral.



ΕΠΙΠΛΟΚΕΣ



ΤΙ ΝΑ
ΘΥΜΑΜΑΙ?

- ΣΩΣΤΗ ΠΡΟΕΤΟΙΜΑΣΙΑ
- ΓΝΩΣΗ ΔΙΑΔΙΚΑΣΙΑΣ
- ΕΞΑΣΚΗΣΗ



ΕΥΧΑΡΙΣΤΩ ΠΟΛΥ ΓΙΑ ΤΗΝ ΠΡΟΣΟΧΗ ΣΑΣ!